This is a digital copy of a book that was preserved for generations on library shelves before it was carefully scanned by Google as part of a project to make the world's books discoverable online.

It has survived long enough for the copyright to expire and the book to enter the public domain. A public domain book is one that was never subject to copyright or whose legal copyright term has expired. Whether a book is in the public domain may vary country to country. Public domain books are our gateways to the past, representing a wealth of history, culture and knowledge that's often difficult to discover.

Marks, notations and other marginalia present in the original volume will appear in this file - a reminder of this book's long journey from the publisher to a library and finally to you.

Usage guidelines

Google is proud to partner with libraries to digitize public domain materials and make them widely accessible. Public domain books belong to the public and we are merely their custodians. Nevertheless, this work is expensive, so in order to keep providing this resource, we have taken steps to prevent abuse by commercial parties, including placing technical restrictions on automated querying.

We also ask that you:

+ *Make non-commercial use of the files* We designed Google Book Search for use by individuals, and we request that you use these files for personal, non-commercial purposes.

+ *Refrain from automated querying* Do not send automated queries of any sort to Google's system: If you are conducting research on machine translation, optical character recognition or other areas where access to a large amount of text is helpful, please contact us. We encourage the use of public domain materials for these purposes and may be able to help.

+ *Maintain attribution* The Google "watermark" you see on each file is essential for informing people about this project and helping them find additional materials through Google Book Search. Please do not remove it.

+ *Keep it legal* Whatever your use, remember that you are responsible for ensuring that what you are doing is legal. Do not assume that just because we believe a book is in the public domain for users in the United States, that the work is also in the public domain for users in other countries. Whether a book is still in copyright varies from country to country, and we can't offer guidance on whether any specific use of any specific book is allowed. Please do not assume that a book's appearance in Google Book Search means it can be used in any manner anywhere in the world. Copyright infringement liability can be quite severe.

About Google Book Search

Google's mission is to organize the world's information and to make it universally accessible and useful. Google Book Search helps readers discover the world's books while helping authors and publishers reach new audiences. You can search through the full text of this book on the web at `http://books.google.com/`

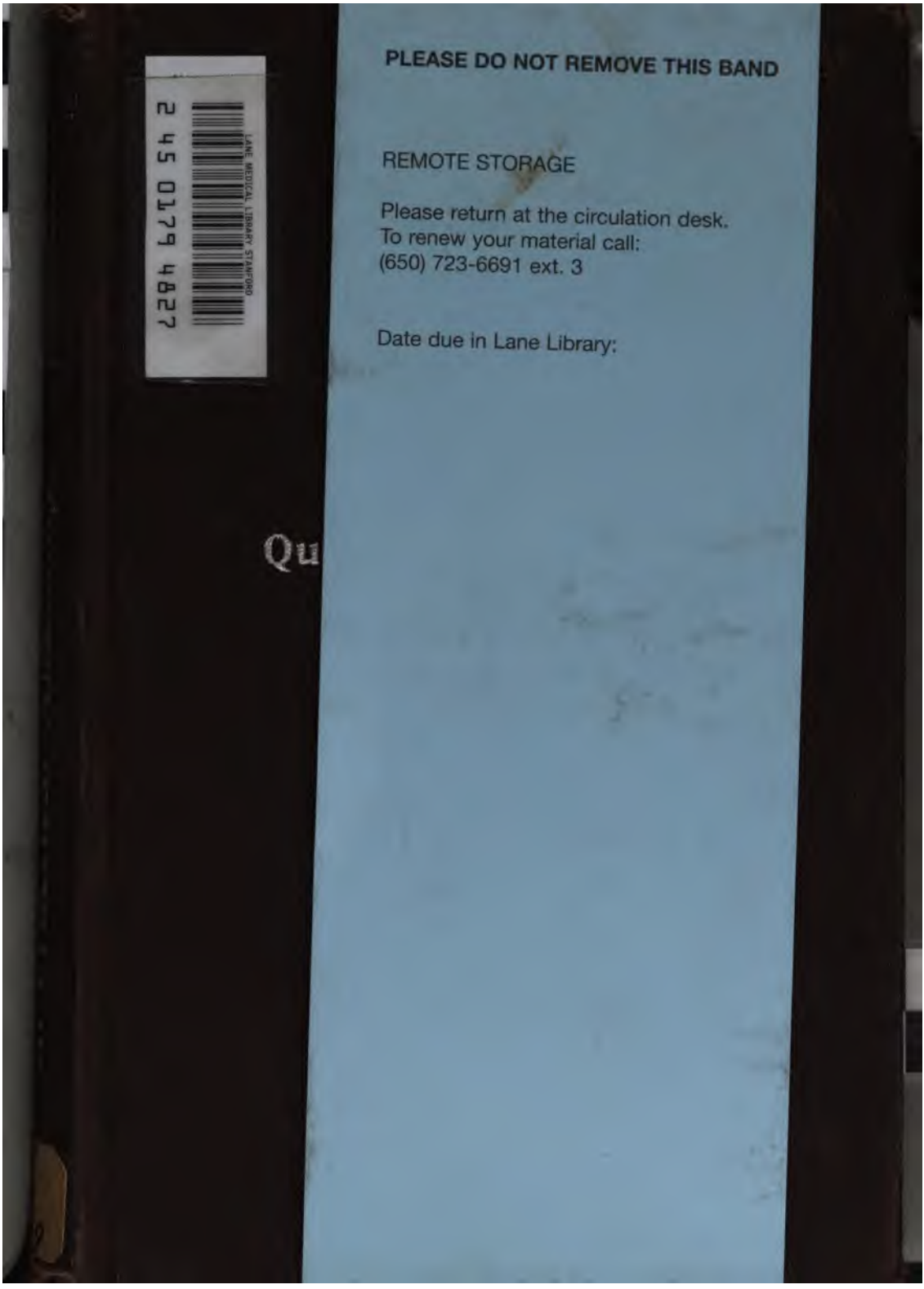
PLEASE DO NOT REMOVE THIS BAND

REMOTE STORAGE

Please return at the circulation desk.
To renew your material call:
(650) 723-6691 ext. 3

Date due in Lane Library:

LANE MEDICAL LIBRARY STANFORD
2 45 0179 4827

Qu

LANE MEDICAL LIBRARY OF
STANFORD UNIVERSITY
300 PASTEUR ROAD
PALO ALTO, CALIFORNIA

Two Thousand Questions

on

Practical Anatomy

prepared for

Students of Medicine and Dentistry

by

George Fetterolf, A. B., M. D.

Assistant Demonstrator of Anatomy, University of Pennsylvania;
Assistant Laryngologist, Methodist Episcopal Hospital

Philadelphia
Lang[illegible] M. D.
[illegible]outh Thirty-[illegible]
1899

SECTION I.

The Head and Neck,

Including the Muscles of the Back

The Common Carotid Artery.

1 *Of what is the left common carotid a branch? The right?*

The aorta. The innominate.

2 *Which is the longer?*

The left.

3 *Where does the common carotid divide?*

At the upper border of the thyroid cartilage.

4 *Into what does it divide?*

External and internal carotid.

5 *Which is the larger?*

The internal.

6 *What* (7) *structures separate the external from the internal carotid?*

The stylo-glossus and stylo-pharyngeus muscles, the glosso-pharyngeal nerve, the pharyngeal branch of the pneumogastric nerve, the stylo-hyoid ligament, the parotid and carotid glands.

7 *Name the* (3) *contents of the carotid sheath?*

Common carotid artery, internal jugular vein, and pneumogastric nerve.

8 *What relation does the vein bear to the artery?*

The vein lies external to the artery.

9 *What special relation, low down on the left side? On the right side?*

The vein crosses the artery. The vein diverges from the artery.

10 *What relation does the nerve bear to the other two structures?*

It lies between and behind.

11 *What* (2) *important structures lie in front of the carotid sheath?*

The descendens hypoglossi nerve and the middle sterno-mastoid artery.

12 *What* (6) *lie internal to the sheath?*

The trachea, larynx, œsophagus, pharynx, thyroid gland, and recurrent laryngeal nerve.

13 *What* (3) *lie behind the sheath?*

The inferior thyroid artery and the sympathetic and recurrent laryngeal nerves.

Branches of the External Carotid.

14 *What are the* (4) *sets of branches of the external carotid?*

Anterior, posterior, ascending, and terminal.

15 *What are the* (3) *anterior branches?*

Superior thyroid, lingual, and facial.

16 *What are the* (4) *branches of the superior thyroid?*

Infra-hyoid, superior laryngeal, middle sterno-mastoid, and crico-thyroid.

17 *How does the superior laryngeal get into the larynx?*

It pierces the thyro-hyoid membrane.

18 *What passes in with it?*

The superior laryngeal nerve.

19 *Of what is the inferior laryngeal artery a branch?*

The inferior thyroid.

20 *Of what is the superior sterno-mastoid artery a branch?*

The occipital.

21 *Of what is the middle sterno-mastoid a branch?*

The superior thyroid.

22 *What* (2) *other arteries have sterno-mastoid branches?*

The suprascapular and the transversalis colli.

23 *What course does the crico-thyroid pursue?*

Transversely across the crico-thyroid membrane.

24 *How many portions has the lingual artery?*

Three.

25 *What are they?*

Oblique, horizontal, and ascending.

26 *What divides it into three portions?*

The hyo-glossus.

27 *How is the triangle of Leser bounded?*

The hypoglossal nerve and the two bellies of the digastric.

28 *What are the* (4) *branches of the lingual artery?*

Supra-hyoid, dorsalis linguæ, sublingual, and ranine.

29 *How many portions has the facial artery?*

Two.

30 *What are they?*

Cervical and facial.

31 *What are the* (5) *branches of the cervical portion?*

Tonsillar, ascending palatine, submaxillary, submental, and muscular.

32 *What gland does the facial artery pass through or under?*

The submaxillary.

33 *What gland does the facial nerve traverse?*

The parotid.

34 *What are the* (6) *branches of the facial portion of the facial artery?*

Muscular, inferior labial, inferior coronary, superior coronary, lateral nasal, and angular.

35 *What relation does the facial vein bear to the facial artery?*

The vein lies posterior to the artery.

36 *What are the* (2) *posterior branches of the external carotid?*

The occipital and the posterior auricular.

37 *What are the three branches of the posterior auricular?*

Auricular, mastoid, and stylo-mastoid.

38 *What canal does the stylo-mastoid enter?*

The facial canal.

39 *How does it get into the canal?*

Through the stylo-mastoid foramen.

40 *What else passes through the foramen?*

The facial nerve.

41 *What winds around the occipital artery?*

The hypoglossal nerve.

42 *What are the* (5) *branches of the occipital?*

Auricular, arteria princeps cervicis, meningeal, superior sterno-mastoid, and muscular.

43 *What are the* (2) *branches of the arteria princeps cervicis?*

Superficial and deep.

44 *With what do they anastomose respectively?*

The superficial and deep cervical.

45 *What is the ascending branch of the external carotid?*

The ascending pharyngeal.

46 *What separates it from the tonsil?*

The superior constrictor of the pharynx.

47 *What other vessel is thus separated from the tonsil?*

The internal carotid.

48 *What are the* (2) *terminal branches of the external carotid?*

The temporal and the internal maxillary.

49 *Where does it divide into its terminal branches?*

At the neck of the condyle of the jaw.

50 *What are the* (5) *branches of the temporal artery?*

Anterior, middle, and posterior temporal, transverse facial, and anterior auricular.

51 *Of what is the posterior auricular a branch?*

The external carotid.

52 *Of what is the deep auricular a branch?*

The internal maxillary.

53 *How many portions has the internal maxillary?*

Three.

54 *What are they?*

Maxillary, pterygoid, and spheno-maxillary.

55 *Between what structures does it run in the first part of its course?*

The neck of the jaw and the pterygo-maxillary ligament.

56 *By what nerve is it crossed in this situation?*

The inferior dental.

57 *In the second portion of its course, between what structures does it lie?*

The pterygoid muscles and the ramus of the jaw.

58 *Between what muscular heads does it pass?*

The external pterygoid and temporal, or the heads of the external pterygoid.

59 *Where is the third portion found?*

In the spheno-maxillary fossa.

60 *How does it get there?*

Through the pterygo-maxillary fissure.

61 *What else passes through this fissure?*

The posterior superior dental nerve.

62 *What are the* (5) *branches of the first portion of the internal maxillary?*

Tympanic, deep auricular, middle and small meningeal, and inferior dental.

63 *How does the tympanic get into tympanum?*

Through the Glaserian fissure.

64 *Between the roots of what nerve does the middle meningeal pass?*

The auriculo-temporal.

65 *How does it get into the cranium?*

Through the foramen spinosum.

66 *How does the small meningeal get into the cranium?*

Through the foramen ovale.

67 *What canal does the inferior dental enter?*

The inferior dental.

68 *What branch does it give off before it enters the canal?*

The mylo-hyoid.

69 *What are its* (2) *terminal branches?*

Mental and incisive.

70 *How does the mental escape on the chin?*

Through the mental foramen.

71 *What are the* (4) *branches of the second portion of the internal maxillary?*

Masseteric, temporal, pterygoid, and buccal.

72 *What are the* (6) *branches of the third portion?*

Alveolar, infraorbital, Vidian, spheno-palatine, pterygo-palatine, and posterior palatine.

The Internal Carotid.

73 *What are the* (4) *portions of the internal carotid?*

Cervical, petrosal, cavernous, and cerebral.

74 *Which portion gives off no branches?*

The cervical.

75 *What separates it from the tonsil?*

The superior constrictor.

76 *What separates it from the internal jugular vein?*

The last four cranial nerves.

77 *What nerves accompany it?*

The ascending branch of the superior cervical ganglion.

78 *What sinus does it pass into?*

The cavernous.

79 *Which wall of the sinus?*

The inner wall.

80 *What are the* (2) *branches of the petrosal portion?*

Tympanic and Vidian.

81 *What canal does the Vidian enter?*

The Vidian canal.

82 *What nerve does it accompany?*

The Vidian nerve.

83 *What are the* (7) *remaining branches?*

Arteriæ receptaculi, anterior meningeal, ophthalmic, posterior communicating, anterior choroid, anterior and middle cerebral.

84 *How does the ophthalmic get into the orbit?*

Through the optic foramen.

85 *What are its* (10) *branches?*

Lachrymal, supraorbital, central artery of the retina, muscular, ciliary, anterior and posterior ethmoidal, palpebral, frontal, and nasal.

86 *How does the ophthalmic vein escape from the orbit?*

Through the sphenoidal fissure.

87 *Between the heads of what?*

The external rectus.

88 *Where does it empty?*

Into the cavernous sinus.

89 *Which fissure lodges the middle cerebral artery?*

The fissure of Sylvius.

90 *What is its most important branch?*

The lenticulo-striate.

91 *Which fissure lodges the anterior cerebrals?*

The great longitudinal.

92 *What connects the two anterior cerebrals?*

The anterior communicating.

93 *What ganglion lies on it?*

The ganglion of Ribes.

94 *What* (5) *vessels form the circle of Willis?*

Anterior and posterior cerebral, anterior

and posterior communicating, and internal carotid.

95 *What is peculiar about the cerebral circulation?*

There is no peripheral anastomosis.

Sinuses of Dura Mater.

96 *Where does the superior longitudinal sinus begin?*

At the foramen cæcum.

97 *What is its shape on cross-section?*

Triangular.

98 *Where is it found?*

Along the upper edge of the falx cerebri.

99 *What bones does it groove?*

The frontal, parietals, and occipital.

100 *Where does it terminate?*

At the torcular Herophili.

101 *What does it become?*

The right lateral sinus.

102 *What fibrous bands cross it?*

The chordæ Willisii.

103 *What structures project into its lumen?*

The Pacchionian bodies.

104 *How do its tributaries empty into it?*

Opposite the direction of the blood current.

105 *Where is the inferior longitudinal sinus found?*

At the lower border of the falx cerebri.

106 *Over what does it arch?*

The corpus callosum.

107 *Where does it terminate?*

In the straight sinus.

108 *What else terminates in the same place?*

The veins of Galen.

109 *Where is the straight sinus found?*

At the junction of the falx cerebri and the tentorium cerebelli.

110 *What* (2) *structures form it?*

The straight sinus and the veins of Galen.

111 *Where does it terminate?*

At the torcular Herophili.

112 *What does it become?*

The left lateral sinus.

113 *Where does the occipital sinus begin? As what?*

At the edge of the foramen magnum. As the marginal sinus.

114 *Where is it found?*

Along the posterior edge of the falx cerebelli.

115 *Where does it terminate?*

At the torcular Herophili.

116 *Where does the lateral sinus begin?*

At the torcular Herophili.

117 *Of what is the right a continuation? The left?*

The superior longitudinal. The straight.

118 *What* (3) *bones does it groove?*

The occipital, parietal, and temporal.

119 *In what order?*

Occipital, parietal, temporal, and occipital.

120 *Which portion of the temporal?*

The mastoid portion.

121 *How is it connected with the cavernous sinus?*

By the superior and inferior petrosal sinuses.

122 *Where does it unite with the inferior petrosal?*

Just below the jugular foramen.

123 *Where does the cavernous sinus begin?*

At the sphenoidal fissure.

124 *What large vein empties into it here?*

The ophthalmic.

125 *What* (3) *structures are found in the outer wall of the cavernous sinus?*

The third and fourth nerves, and the first division of the fifth nerve.

126 *What* (2) *in the inner wall?*

The sixth nerve and the internal carotid.

127 *What separates these structures from the blood current?*

Endothelium.

128 *Into what does the cavernous sinus divide?*

Superior and inferior petrosal.

129 *With what do they connect the cavernous?*

The lateral sinus.

130 *What connects the two cavernous sinuses?*

The circular sinus.

131 *What does the circular surround?*

The pituitary body.

132 *Where is the superior petrosal found?*

Along the upper margin of the petrous portion of the temporal bone.

133 *What does it connect?*

The same as the inferior.

134 *What connects the inferior petrosals?*

The transverse or basilar sinus.

135 *How does the inferior petrosal escape from the cranium?*

Through the anterior compartment of the jugular foramen.

136 *How does the lateral escape?*

Through the posterior compartment of the jugular foramen.

137 *What do they unite to form?*

The internal jugular vein.

138 *What* (3) *structures pass between them?*

The ninth, tenth, and eleventh nerves.

The Jugular Veins.

139 *What are the four pairs of jugular veins?*

Internal, external, anterior, and posterior external.

140 *Where does the internal jugular vein begin?*

Below the jugular foramen.

141 *What artery does it accompany in the upper part of the neck?*

The internal carotid.

142 *What* (4) *structures separate it from the artery?*

The last four cranial nerves.

143 *What artery does it accompany in the lower part of the neck?*

The common carotid.

144 *With what does it join?*

The subclavian.

145 *To form what?*

The innominate.

146 *Where does the external jugular vein begin?*

At the angle of the jaw.

147 *What veins unite to form it?*

The posterior auricular and the temporomaxillary.

148 *What is the line for it?*

From the angle of the jaw to the middle of the clavicle.

149 *Where does it empty?*

Into the subclavian.

150 *Where does the posterior external jugular empty?*

Into the external.

151 *Where does the anterior jugular begin?*

Below the chin.

152 *Into what two places may it empty?*

The external jugular or the subclavian.

153 *What space does it sometimes pass through?*

The space of Burns.

The Deep Cervical Fascia.

154 *What is the deep cervical fascia attached to posteriorly?*

The ligamentum nuchæ and the spines of the vertebræ.

155 *What does it first surround as it passes forward?*

The trapezius.

156 *What space does it then roof over?*

The posterior triangle.

157 *What does it then surround?*

The sterno-mastoid.

158 *What space does it then roof over?*

The anterior triangle.

159 *Where does it meet its fellow?*

In the middle line.

160 *What does it do low down in front?*

It splits into two lamellæ.

161 *Where are they attached?*

To the margins of the sternum.

162 *What is the space between them?*

The space of Burns.

163 *What passes through this space sometimes?*

The anterior jugular veins.

164 *What* (2) *processes are found on the face?*

The parotid and masseteric fascias.

165 *What process is found internal to the jaw?*

The stylo-maxillary ligament.

166 *What* (2) *structures are separated by this ligament?*

The parotid and submaxillary glands.

167 *What* (2) *large processes are given off in the neck?*

The pretracheal and prevertebral fascias.

168 *What two compartments are formed thereby?*

The muscular and the visceral.

169 *What becomes of the pretracheal fascia in the thorax?*

It blends with the fibrous layer of the pericardium.

170 *How is the carotid sheath formed?*

By processes from the pretracheal and prevertebral fascias.

The Cervical Plexus.

171 *What nerves form the cervical plexus?*

The anterior primary divisions of the upper four cervical.

172 *What are the* (2) *sets of branches of the cervical plexus?*

Superficial and deep.

173 *What do the superficial wind around? Which border?*

The sterno-mastoid. Posterior.

174 *What triangle are they in?*

The occipital.

175 *What are the* (3) *sets of superficial branches?*

Ascending, transverse, and descending.

176 *What are the* (2) *ascending branches?*

Auricularis magnus and occipitalis minor.

177 *What are the* (3) *branches of the auricularis magnus?*

Mastoid, auricular, and facial.

178 *What is the posterior auricular nerve?*

A branch of the facial.

179 *What is the auriculo-temporal nerve?*

A branch of the inferior maxillary.

180 *What are the* (3) *branches of the occipitalis minor?*

Occipital, mastoid, and auricular.

181 *What is the suboccipital nerve?*

The posterior division of the first cervical nerve.

182 *What is the great occipital nerve?*

The internal branch of the posterior division of the second cervical nerve.

183 *What is the smallest occipital nerve?*

The internal branch of the posterior division of the third cervical nerve.

184 *What is the transverse branch of the superficial division of the cervical plexus?*

The superficialis colli.

185 *What is its distribution?*

From the chin to the sternum.

186 *What are the* (3) *descending branches?*

Supra-sternal, supra-clavicular, and supra-acromial.

187 *What are the* (2) *sets of the deep division of the cervical plexus?*

Internal and external.

188 *What are the* (2) *external branches?*

Muscular and communicating.

189 *What are the* (4) *internal branches?*

Muscular, communicating, communicantes hypoglossi, and phrenic.

190 *With what do the communicantes hypoglossi inosculate?*

The descendens hypoglossi.

191 *To form what? Where?*

The ansa hypoglossi. In front of the carotid sheath.

192 *What does this loop supply?*

The infra-hyoid muscles.

193 *From what nerves does the phrenic come?*

The third, fourth, and fifth cervical.

194 *On what muscle does it lie?*

The scalenus anticus.

195 *Between what muscles does it pass?*

The subclavian artery and vein.

196 *Over the root of what vessel does it pass?*

The internal mammary.

197 *Into what mediastina?*

Superior and middle.

198 *Between what membranes?*

The pericardium and pleura.

199 *What does it supply?*

The diaphragm.

200 *Which surface?*

The lower.

201 *Which phrenic is the longer? Why?*

The left. It winds around the heart and the diapragm is lower on the left side.

The Triangles of the Neck.

202 *How is the inferior carotid triangle bounded?*

The middle line, the sterno-mastoid, and the omo-hyoid.

203 *What* (3) *structures form its floor?*

The scalenus anticus, longus colli, and rectus capitis anticus major.

204 *What are its contents?* a. *In the sheath* (3)*?* b. *In the front of the sheath* (2)*?* c. *Internal to the sheath* (3)*?* d. *Behind the sheath* (3)*?*

a. The common carotid artery, internal jugular vein, and pneumogastric nerve. b. Descendens hypoglossi and middle sterno-mastoid artery. c. Trachea, larynx, and thyroid gland. d. Sympathetic and recurrent laryngeal nerves and inferior thyroid artery.

205 *How is the superior carotid triangle bounded?*

The sterno-mastoid, the omo-hyoid, and the digastric (posterior belly).

206 *What* (4) *structures form its floor?*

The thyro-hyoid, hyo-glossus, and middle and inferior constrictors.

207 *What are its contents?* a. *What* (8) *ar-*

teries? b. *What* (6) *veins?* c. *What* (7) *nerves?*

a. Common, external and internal carotid, superior thyroid, lingual, facial, occipital, and ascending pharyngeal. b. Superior thyroid, lingual, facial, occipital, ascending pharyngeal, and internal jugular. c. Pneumogastric, superior and external laryngeal, spinal accessory, hypoglossal, descendens hypoglossi, and sympathetic.

208 *How is the submaxillary triangle bounded?*

The two bellies of the digastric, and the lower jaw and a line to the mastoid process.

209 *What* (2) *structures form its floor?*

The mylo-hyoid and hyo-glossus.

210 *What divides it into two portions?*

The stylo-maxillary ligament.

211 *What are the contents of the anterior portion?* a. *What gland?* b. *What artery and vein?* c. *What artery, vein, and nerve?* d. *What small artery?*

a. Submaxillary. b. Facial. c. Mylo-hyoid d. Submental.

212 *What are the contents of the posterior portion?* a. *What* (5) *arteries?* b. *What* (4) *veins?* c. *What* (5) *nerves?* d. *What* (2) *muscles?* e. *What ligament?*

a. External and internal carotid, posterior auricular, temporal and internal maxillary. b. Posterior auricular, temporal, internal maxillary, and internal jugular. c. Ninth, tenth,

eleventh, twelfth, and sympathetic. d. Stylo-glossus and stylo-pharyngeus. e. Stylo-hyoid.

213 *How is the occipital triangle bounded?*

The sterno-mastoid, the omo-hyoid and the trapezius.

214 *What* (4) *structures form its floor?*

The splenius, levator anguli scapulæ, scalenus medius, and scalenus posticus.

215 *What are its contents?* a. *What spinal nerves?* b. *What cranial nerve?* c. *What artery and vein?* d. *What lymphatics?*

a. The superficial branches of the cervical plexus. b. The spinal accessory. c. Transversalis colli. d. A chain of lymphatics.

216 *How is the subclavian triangle bounded?*

The sterno-mastoid, the omo-hyoid, and the clavicle.

217 *What* (2) *structures form its floor?*

The first rib and the first digitation of the serratus magnus.

218 *What are its contents?* a. *What* (3) *arteries?* b. *What* (5) *veins?* c. *What plexus?* d. *What small nerve?* e. *What lymphatic structure?*

a. Subclavian, suprascapular, and transversalis colli. b. Subclavian, suprascapular, transversalis colli, external jugular, and jugulo-cephalic. c. Brachial. d. The nerve to the subclavius muscle. e. A lymphatic gland.

The Salivary Glands.

219 *Name the* (3) *pairs of salivary glands?*
Parotid, submaxillary and sublingual.
220 *Which is the largest?*
The parotid.
221 *How is the parotid bounded above? Below? Behind? In front?*
By the zygoma. By a line from the angle of the mandible to the mastoid process. By the external auditory meatus, the mastoid process, and the digastric and sternomastoid muscles. By the masseter muscle.
222 *What are the* (4) *lobes of the parotid gland?*
Glenoid, carotid, pterygoid, and the socia parotidis.
223 *Where is the socia parotidis located?*
On the masseter above Stenson's duct.
224 *What* (3) *nerves are there in the parotid?*
Facial, great auricular, and auriculo-temporal.
225 *What* (5) *arteries are there in the parotid?*
External carotid, temporal, internal maxillary, transverse facial, and anterior auricular.
226 *What* (2) *veins are there in the parotid?*
The temporo-maxillary and a communicating branch to the internal jugular.
227 *What is the duct of the parotid?*

Stenson's duct.

228 *What muscle does it cross?*

The masseter.

229 *What muscle does it pierce?*

The buccinator.

230 *What empties into it?*

The duct of the socia parotidis.

231 *Where does it empty?*

Into the mouth opposite the second upper molar tooth.

232 *What separates the parotid from the submaxillary gland?*

The stylo-maxillary ligament.

233 *On what muscles does the submaxillary rest?*

Mylo-hyoid, hyo-glossus, and stylo-glossus.

234 *What artery and vein run through or under it?*

The facial.

235 *What is its duct?*

Wharton's duct.

236 *What muscle does the duct wind around?*

The mylo-hyoid.

237 *Between what pairs of muscles does it run?*

Mylo-hyoid and hyo-glossus; mylo-hyoid and genio-hyo-glossus.

238 *Between what other pairs of structures does it pass?*

The lingual and hypoglossal nerves; the sublingual gland and the genio-hyo-glossus.

239 *Where does it empty?*
Into the side of the frænum linguæ.
240 *Which is the smallest pair of salivary glands?*
The sublingual.
241 *What separates the sublingual and submaxillary glands?*
The mylo-hyoid muscle.
242 *What separates the sublingual gland from the mouth?*
Mucous membrane.
243 *What is the large duct of the sublingual gland?*
The duct of Bartholine.
244 *Where does it empty?*
Into Wharton's duct.
245 *What are the small ducts of the sublingual?*
The ducts of Rivini.
246 *Where do they empty?*
Into the frænum linguæ.

The Facial Nerve.

247 *How does the facial nerve escape from the cranium?*
Through the internal auditory meatus.
248 *What canal does it enter?*
The facial canal or aqueductus Fallopii.
249 *How does it leave this canal?*
Through the stylo-mastoid foramen.

250 *What* (6) *branches does it give off in the facial canal?*

Chorda tympani, nerve to the stapedius muscle, communicating to the vagus, and the great, small, and external superficial petrosal nerves.

251 *What* (3) *branches does it give off after leaving the stylo-mastoid foramen?*

Posterior auricular, stylo-hyoid, and digastric.

252 *What does the posterior auricular supply?*

The occipitalis and the retrahens and attolens aurem.

253 *What does the stylo-hyoid supply?*

The corresponding muscle.

254 *What does the digastric branch supply?*

The posterior belly of the digastric.

255 *What supplies the anterior belly?*

The mylo-hyoid nerve.

256 *What gland does the facial nerve traverse?*

The parotid.

257 *What plexus does it spread out into?*

The pes anserinus.

258 *What* (2) *great divisions does it form?*

The temporo-facial and cervico-facial.

259 *What are the* (3) *branches of the temporo-facial?*

Temporal, malar, and infraorbital.

260 *What are the* (3) *branches of the cervico-facial?*

Buccal, supramaxillary, and inframaxillary.

261 *What nerve supplies the muscles of expression?*

The facial.

The Trifacial Nerve.

262 *What nerve supplies the muscles of mastication?*

The trifacial.

263 *What are the* (5) *muscles of mastication?*

Masseter, temporal, buccinator, and external and internal pterygoids.

264 *Which has two heads?*

The external pterygoid.

265 *What passes between the heads?*

The buccal and anterior deep temporal nerves.

266 *What are the* (3) *branches of the fifth nerve?*

Ophthalmic, superior maxillary, and inferior maxillary.

267 *How does the ophthalmic get into the orbit?*

Through the sphenoidal fissure.

268 *What are its branches?*

Nasal, frontal, and lachrymal.

269 *Into what does the frontal divide?*

Supraorbital and supratrochlear.

270 *How does the superior maxillary escape from the cranium?*

Through the foramen rotundum.

271 *Into what fossa does it pass?*
The spheno-maxillary fossa.
272 *How does it escape from the fossa?*
Through the spheno-maxillary fissure.
273 *Into what does it then pass?*
The infraorbital groove and canal.
274 *How does it escape on to the face?*
Through the infraorbital foramen.
275 *What branch does it give off in the cranium?*
The recurrent branch.
276 *What* (3) *branches in the spheno-maxillary fossa?*
Spheno-palatine, orbital, and posterior superior dental.
277 *What* (2) *branches in the infraorbital canal?*
Middle and anterior superior dental.
278 *What* (3) *branches on the face?*
Labial, nasal, and palpebral.
279 *With what do these inosculate?*
The infraorbital branch of the facial.
280 *To form what?*
The infraorbital plexus.
281 *How does the inferior maxillary escape from the cranium?*
Through the foramen ovale.
282 *What branches does it give off before dividing?*
Recurrent and internal pterygoid.
283 *Into what does it divide?*
Anterior and posterior divisions.

284 *What* (5) *branches does the anterior division give off?*

Masseteric, anterior and posterior deep temporal, buccal, and external pterygoid.

285 *What* (3) *branches does the posterior division give off?*

Auriculo-temporal, lingual, and inferior dental.

286 *How many roots has the auriculo-temporal?*

Two.

287 *What passes between them?*

The middle meningeal artery.

288 *What kind of a nerve is the lingual?*

Sensory.

289 *What are the motor nerves of the tongue?*

The hypoglossal and the chorda tympani.

290 *What are the nerves of special sense to the tongue?*

The glosso-pharyngeal and the chorda tympani.

291 *What is the nerve of common sensation to the tongue?*

The lingual.

292 *What branch does the inferior dental give off?*

The mylo-hyoid.

293 *What does the mylo-hyoid supply?*

The mylo-hyoid muscle and the anterior belly of the digastric.

294 *What are the terminal branches of the inferior dental?*

Mental and incisive.

The Glosso-pharyngeal Nerve.

295 *How does the glosso-pharyngeal nerve escape from the cranium?*

Through the middle compartment of the jugular foramen.

296 *Between what vessels does it pass?*

The internal carotid and the internal jugular.

297 *What are its* (7) *branches?*

Recurrent, communicating, tympanic, muscular, pharyngeal, tonsillar, and lingual.

The Pneumogastric Nerve.

298 *How does the pneumogastric escape from the cranium?*

Through the middle compartment of the jugular foramen.

299 *What vessels does it separate?*

The internal carotid and the internal jugular.

300 *Where does it lie?*

In the carotid sheath.

301 *What are its* (6) *branches in the neck?*

Recurrent, communicating, auricular, pharyngeal, superior laryngeal, and cervical cardiac.

302 *Into what does the superior laryngeal divide?*

Internal and external.

303 *How does the internal get into the larynx?*

Through the thyro-hyoid membrane.

304 *What does it supply?*

The laryngeal mucous membrane.

305 *What does the external supply?*

The crico-thyroid muscle.

306 *What supplies the other laryngeal muscles?*

The recurrent laryngeal nerve.

307 *Where does the left inferior cervical cardiac go?*

To the superficial cardiac plexus.

308 *Where do the other cardiac branches of the pneumogastric go?*

To the deep cardiac plexus.

The Spinal Accessory Nerve.

309 *How does the spinal accessory escape form the cranium?*

Through the middle compartment of the jugular foramen.

310 *Between what vessels does it pass?*

The internal carotid and the internal jugular.

311 *What triangle does it first cross?*

The superior carotid.

312 *What muscles does it pierce?*
The sterno-mastoid.
313 *What triangle does it then cross?*
The occipital.
314 *What muscle does it then supply?*
The trapezius.
315 *What plexus does it help to form?*
The subtrapezial.

The Hypoglossal Nerve.

316 *How does the hypoglossal nerve escape from the cranium?*
Through the anterior condyloid foramen.
317 *Between what vessels does it pass?*
The internal carotid and the internal jugular.
318 *What vessel does it wind around?*
The occipital artery.
319 *What apparent branch does it give off?*
The descendens hypoglossi.
320 *With what does the descendens hypoglossi inosculate?*
The communicantes hypoglossi.
321 *To form what?*
The ansa hypoglossi.
322 *Where does the ansa hypoglossi lie?*
In front of the carotid sheath.
323 *What does it supply?*
The infra-hyoid muscles.

The Eyelids.

324 *What are the* (7) *layers of the eyelids?*

Skin, superficial fascia, orbicularis palpebrarum, levator palpebræ (in the upper lid only), tarsal plate, Meibomian glands, and conjunctiva.

The Muscles.

325 *Where does the serratus posticus superior arise?*

The lower part of the ligamentum nuchæ, the spines of the last cervical and first two thoracic vertebræ, and the connecting ligaments.

326 *Where does it insert?*

The second to the fifth ribs, external to their angles.

327 *Where does the serratus posticus inferior arise?*

The spines of the last two thoracic and first two lumbar vertebræ.

328 *Where does it insert?*

The last four or five ribs external to their angle.

329 *Where does the splenius capitis arise?*

The lower two-thirds of the ligamentum nuchæ, the spines of the seventh cervical and last two thoracic vertebræ, and the interspinous ligaments.

330 *Where does it insert?*

The mastoid process and the outer third of the middle nuchal line of the occipital bone.

331 *Where does the splenius colli arise?*

The spines of the third to the sixth thoracic vertebræ and the interspinous ligaments.

332 *Where does it insert?*

The transverse processes of the three or four upper cervical vertebræ.

333 *Where does the erector spinæ arise?*

The spines of the last two thoracic, all the lumbar and the four upper sacral vertebræ, the side of the fourth sacral vertebra, the posterior sacro-iliac ligaments, the posterior superior iliac spine, and the iliac crest.

334 *Where does it insert?*

It is a continuation of the spinalis and longissimus dorsi and the ilio-costalis.

335 *Where does the ilio-costalis arise?*

The outer portion of the erector spinæ.

336 *Where does it insert?*

The angles of the sixth to the eleventh ribs, the lower border of the last rib, and the transverse processes of the lumbar vertebræ.

337 *Where does the accessorius arise?*

The angles of the seventh to the eleventh ribs and the last rib.

338 *Where does it insert?*

The transverse process of the seventh

cervical vertebra and the first to the fifth ribs.

339 *Where does the cervicalis ascendens arise?*

The back of the four or five upper ribs.

340 *Where does it insert?*

The transverse processes of the fourth, fifth, and sixth cervical vertebræ.

341 *Where does the longissimus dorsi arise?*

The middle of the erector spinæ and the transverse processes of the lower thoracic vertebræ.

342 *Where does it insert?*

The transverse processes of the upper lumbar vertebræ and the lower border of the ribs; internally into the thoracic and upper lumbar vertebræ.

343 *Where does the transversalis colli arise?*

The transverse processes of the five or six upper thoracic vertebræ.

344 *Where does it insert?*

The transverse processes of the second to the sixth cervical vertebræ.

345 *Where does the trachelo-mastoid arise?*

The lower four cervical and the upper five thoracic vertebræ.

346 *Where does it insert?*

The posterior border of the mastoid process.

347 *Where does the spinalis dorsi arise?*

The erector spinæ.

348 *Where does it insert?*

The spines of the upper thoracic vertebræ.

349 *Where does the complexus arise?*

The articular processes of the third to the sixth cervical vertebræ, the transverse processes of the seventh cervical and upper six thoracic vertebræ, and the spine of the seventh cervical vertebra.

350 *Where does it insert?*

The occipital bone between the middle and inferior curved lines.

351 *Where does the semispinalis dorsi arise?*

The transverse processes of the sixth to the tenth thoracic vertebræ.

352 *Where does it insert?*

The spines of the last two cervical and first four thoracic vertebræ.

353 *Where does the semispinalis colli arise?*

The transverse processes of the upper five or six thoracic vertebræ.

354 *Where does it insert?*

The spines of the second to the fifth cervical vertebræ.

355 *Where does the multifidus arise?*

The sacrum, posterior sacro-iliac ligaments, the erector spinæ, the lumbar vertebræ, the transverse processes of the thoracic vertebræ, and the fourth to the seventh cervical vertebræ.

356 *Where does it insert?*

The spines of the vertebræ from the last lumbar to the second cervical.

357 *Where do the rotatores spinæ arise?*
The transverse process.
358 *Where do they insert?*
The lamina of the vertebra next above.
359 *Where do the interspinales arise?*
The spine of the vertebra.
360 *Where do they insert?*
The spine of the vertebra next above.
361 *Where do the intertransversales arise and insert?*
They pass between adjacent transverse processes.
362 *Where does the rectus capitis posticus major arise?*
The spine of the axis.
363 *Where does it insert?*
The middle third of the inferior nuchal line.
364 *Where does the rectus capitis posticus minor arise?*
The posterior tubercle of the atlas.
365 *Where does it insert?*
The inner third of the inferior nuchal line.
366 *Where does the superior oblique arise?*
The transverse process of the atlas.
367 *Where does it insert?*
Behind the outer half of the inferior nuchal line.
368 *Where does the inferior oblique arise?*
The spine of the axis.
369 *Where does it insert?*

The transverse process of the atlas.

370 *Where does the rectus capitis lateralis arise?*

The lateral mass of the atlas.

371 *Where does it insert?*

The jugular process of the occipital bone.

372 *Where does the platysma myoides arise?*

The deep fascia of the front of the chest and shoulder and the deep cervical fascia over the sterno-mastoid.

373 *Of what is it an occupant?*

The superficial fascia.

374 *Where does it insert?*

The body of the jaw and the skin from the masseter to the angle of the mouth.

375 *Where does the occipitalis arise?*

The outer two-thirds of the superior nuchal line and the mastoid process.

376 *Where does it insert?*

The epicranial aponeurosis.

377 *Where does the frontalis arise?*

The skin of the eyebrow and the root of the nose.

378 *Where does it insert?*

The epicranial aponeurosis.

379 *What two portions has the orbicularis palpebrarum?*

Orbital and palpebral.

380 *What are its origin and insertion?*

The internal angular process, the nasal process of the maxilla and the inner tarsal ligament.

381 *What is Horner's muscle?*
The tensor tarsi.
382 *Where does it arise?*
The lachrymal crest.
383 *Where does it insert?*
The inner end of the tarsal plates.
384 *Where does the corrugator supercilii arise?*
The inner end of the superciliary ridge.
385 *Where does it insert?*
The skin at the middle of the eyebrow.
386 *Where does the attollens aurem arise?*
The epicranial aponeurosis.
387 *Where does it insert?*
The inner surface of the pinna.
388 *Where does the attrahens aurem arise?*
The epicranial aponeurosis.
389 *Where does it insert?*
The inner surface of the helix.
390 *Where does the retrahens aurem arise?*
The mastoid process.
391 *Where does it insert?*
The inner surface of the concha.
392 *Where does the pyramidalis nasi arise?*
The upper border of the nasal aponeurosis.
393 *Where does it insert?*
The skin between the eyebrows.
394 *Where does the compressor narium arise?*
The nasal aponeurosis.
395 *Where does it insert?*

The canine fossa and into adjacent muscles.

396 *Where does the depressor alæ nasi arise?*

From the incisive fossa.

397 *Where does it insert?*

The cartilage of the ala and the septum.

398 *Where does the dilatator naris anterior arise?*

The lateral nasal cartilage.

399 *Where does it insert?*

The skin over the ala.

400 *Where does the dilatator naris posterior arise?*

From the edge of the nasal aperture of the maxilla and the nasal sesamoid cartilages.

401 *Where does it insert?*

The skin over the alar cartilage.

402 *What fixed attachments has the orbicularis oris?*

The septal cartilage and the incisive fossa of both maxillæ.

403 *Where does the buccinator arise?*

The alveolar process of the upper and lower jaws at the last two molars and the pterygo-maxillary ligament, inserting into the orbicularis oris.

404 *Where does the zygomaticus major arise?*

The malar bone near the zygomatic suture.

405 *Where does it insert?*

The skin at the angle of the mouth.

406 *Where does the zygomaticus minor arise?*

The front of the malar bone.

407 *Where does it insert?*

The skin of the upper lip between the middle and the angle of the mouth.

408 *Where does the levator anguli oris arise?*

The canine fossa of the upper jaw.

409 *Where does it insert?*

The skin external to the angle of the mouth.

410 *Of what is the risorius part?*

The platysma myoides.

411 *Where does it arise?*

The subcutaneous tissue over the masseter and parotid gland.

412 *Where does it insert?*

Similar tissue external to the angle of the mouth.

413 *Where does the depressor anguli oris arise?*

The lower maxilla below the canine, premolar, and first molar teeth.

414 *Where does it insert?*

At the angle of the mouth.

415 *Where does the levator labii superioris alæque nasi arise?*

The nasal process of the upper maxilla.

416 *Where does it insert?*

The skin at the ala of the nose and the inner half of the upper lip.

417 *Where does the levator labii superioris arise?*

The superior maxilla below the orbit.

418 *Where does it insert?*

The skin of the inner half of the upper lip.

419 *Where does the depressor labii inferioris arise?*

The lower jaw below the canine and premolar teeth.

420 *Where does it insert?*

The skin at the edge of the lower lip.

421 *Where does the depressor alæ nasi arise?*

The incisive fossa.

422 *Where does it insert?*

The septum and ala.

423 *Where does the masseter arise?*

As a superficial and a deep layer from the malar bone and the zygomatic arch.

424 *Where does it insert?*

The outer surface of the ramus of the lower jaw.

425 *Where does the temporal arise?*

From the temporal fossa and temporal fascia.

426 *Where does it insert?*

The coronoid process of the lower jaw down to the last molar tooth.

427 *How many heads has the external pterygoid?*

Two: an upper and a lower.

428 *What* (2) *nerves run between the heads?*

The buccal and anterior deep temporal.

429 *Where does the upper head arise?*

The great wing of the sphenoid.

430 *Where does the lower head arise?*

The outer surface of the external pterygoid plate.

431 *Where does the upper head insert?*

The interarticular fibro-cartilage, the capsular ligament, and the neck of the condyle of the inferior maxilla.

432 *Where does the lower head insert?*

In front of the neck of the condyle.

433 *Where does the internal pterygoid arise?*

The inner surface of the external pterygoid plate, the tuberosity of the palate bone, and the superior maxilla adjacent to it.

434 *Where does it insert?*

The lower half of the inner surface of the ramus of the jaw.

435 *Where does the sterno-cleido-mastoid arise?*

The sternal head from the manubrium and the clavicular head from the inner third of the clavicle.

436 *Where does it insert?*

The mastoid process and outer half of the superior nuchal line.

437 *Where does the sterno-hyoid arise?*

The manubrium, the posterior sterno-clavicular ligament, and the back of the clavicle.

438 *Where does it insert?*

The body of the hyoid bone.

439 *How many bellies has the omo-hyoid?*
Two.
440 *Where does it arise?*
The upper border of the scapula and the transverse ligament.
441 *Where does it insert?*
The body of the hyoid bone external to the sterno-hyoid.
442 *Where does the sterno-thyroid arise?*
The manubrium, the first costal cartilage, and the back of the clavicle.
443 *Where does it insert?*
The oblique line of the thyroid cartilage.
444 *Where does the thyro-hyoid arise?*
The oblique line of the thyroid cartilage.
445 *Where does it insert?*
The body and greater corner of the hyoid bone.
446 *How many bellies has the digastric?*
Two.
447 *Where does it arise?*
The digastric fossa.
448 *What muscle does it perforate?*
The stylo-hyoid.
449 *Where does it insert?*
The body of the lower jaw external to the symphysis.
450 *Where does the stylo-hyoid arise?*
The styloid process.
451 *Where does it insert?*
The body of the hyoid bone.
452 *Where does the mylo-hyoid arise?*

The mylo-hyoid ridge.

453 *Where does it insert?*

The body of the hyoid bone and the median raphe from the hyoid bone to the genial tubercle.

454 *Where does the genio-hyoid arise?*

The lower genial tubercle.

455 *Where does it insert?*

The body of the hyoid bone.

456 *Where does the genio-hyo-glossus arise?*

The upper genial tubercle.

457 *Where does it insert?*

The under surface of the tongue, the body of the hyoid bone, and the pharynx.

458 *Where does the hyo-glossus arise?*

From the body and both cornua of the hyoid bone.

459 *Where does it insert?*

The posterior half of the under surface of the tongue.

460 *Where does the stylo-glossus arise?*

The styloid process and the stylo-maxillary ligament.

461 *Where does it insert?*

The side and under surface of the tongue.

462 *Where does the palato-glossus arise?*

The palatal aponeurosis.

463 *Where does it insert?*

The under surface of the tongue.

464 *What does it form?*

The anterior pillar of the fauces.

465 Where does the scalenus anticus arise?

The transverse processes of the third to the sixth cervical vertebræ.

466 *Where does it insert?*

The scalene tubercle of the first rib.

467 *What nerve lies on it?*

The phrenic.

468 *What vessels does it separate?*

The subclavian artery and vein.

469 *Where does the scalenus medius arise?*

The six lower cervical vertebræ.

470 *Where does it insert?*

The first rib.

471 *What nerve arises in it?*

The posterior thoracic.

472 *Where does the scalenus posticus arise?*

The posterior tubercles of the two or three lower cervical vertebræ.

473 *Where does it insert?*

The second rib.

474 *Where does the rectus capitis anticus major arise?*

The anterior tubercles of the third to the sixth cervical vertebræ.

475 *Where does it insert?*

The basilar process of the occipital bone.

476 *Where does the rectus capitis anticus minor arise?*

The lateral mass of the atlas.

477 *Where does it insert?*

The basilar process of the occipital bone in front of the foramen magnum.

478 *Where does the longus colli arise?*

From the third cervical to the third thoracic vertebræ.

479 *Where does it insert?*

The upper six cervical vertebra.

SECTION II.

The Thorax and Abdomen.

The Mediastinal Space.

1 *What are the* (2) *viscera of the thorax?*
The heart and the lungs.
2 *What is the mediastinal space?*
The space between the pleuræ.
3 *How is it bounded laterally?*
By the pleuræ.
4 *What are its* (4) *subdivisions?*
The superior, anterior, middle, and posterior mediastina.
5 *What are the* (3) *structures bounding the superior mediastinum in front?*
The manubrium of the sternum and the origins of the sterno-hyoid and sterno-thyroid muscles.
6 *What* (2) *structures bound it behind?*
The bodies of the first four thoracic vertebræ and the lower portions of the longus colli muscles.
7 *How is it bounded laterally?*
By the pleural sacs.
8 *What is its upper limit? Its lower limit?*
The upper opening of the thorax. A plane passing from the junctions of the

first and second pieces of the sternum to the lower border of the body of the fourth thoracic vertebra.

9 *What are the contents of the superior mediastinum?* a. *What portion of the respiratory system?* b. *What portion of the alimentary system?* c. *What portion of the lymphatic system?* d. *What* (5) *arteries?* e. *What* (2) *veins?* f. *What* (4) *nerves?* g. *What* (2) *glands?* h. *What ligaments?*

a. The trachea. b. The œsophagus. c. The thoracic duct. d. The arch of the aorta and the innominate, left common carotid, left subclavian and thyroidea ima arteries. e. The innominate and superior vena cava. f. The pneumogastric, left recurrent laryngeal, phrenic and cardiac. g. The thymus and bronchial lymphatic. h. The superior sterno-pericardiac.

10 *What determines the middle mediastinum?*

The pericardium.

11 *What are its contents?* a. *What viscus?* b. *What* (3) *arteries?* c. *What* (2) *veins?* d. *What pair of nerves?* e. *What* (2) *other structures?*

a. The heart. b. The aorta, pulmonary and comes nervi phrenici. c. The superior vena cava and vena azygos major. d. The phrenic. e. The roots of the lungs and bronchial lymphatic glands.

12 *What is the anterior boundary of the anterior mediastinum?*

The sternum, the fourth, fifth, sixth and seventh costal cartilages and the triangularis sterni muscle.

13 *What is the posterior boundary?*

The pericardium.

14 *What are its contents?* a. *What* (2) *glands.* b. *What ligaments?*

a. Lymphatic and thymus. b. The superior sterno-pericardiac.

15 *What* (2) *structures bound the posterior mediastinum in front?*

The roots of the lungs and the pericardium.

16 *What is its posterior boundary?*

The vertebral column below the fourth thoracic vertebra.

17 *What is its lateral boundary?*

The pleuræ.

18 *What are its contents?* a. *What artery?* b. *What veins?* c. *What* (2) *portions of the lymphatic system?* d. *What portion of the alimentary canal?* e. *What pair of nerves?*

a. The aorta. b. The azygos. c. The thoracic duct and lymphatic glands. d. The œsophagus. e. The pneumogastric.

The Lungs.

19 *What surrounds the lungs?*

The pleura.

20 *How many layers has it?*

Two.

21 *What are they called?*

Parietal and visceral.

22 *Which is in relation with the lung tissue?*

The visceral layer.

23 *What fold of pleura descends on each side to the diaphragm?*

The ligamentum latum pulmonis.

24 *To what is it attached above?*

The root of the lung.

25 *How high in the neck do the pleuræ rise?*

An inch above the first rib.

26 *How many lobes has the right lung? The left?*

~~Two~~ Three. Left two. right three.

27 *Which lung is the larger?*

The right.

28 *Which is the shorter?*

The right.

29 *Which is the broader?*

The right.

30 *What are the* (3) *main structures forming the root of the lung?*

Bronchus, pulmonary artery, and pulmonary vein.

31 *What is the relation of these from above downward on the right side? On the left side?*

Bronchus, artery, and vein. Artery, bronchus, and vein.

32 *What is the arrangement from before backward?*

Vein, artery, and bronchus.

The Heart.

33 *What surrounds the heart?*

The pericardium.

34 *What* (2) *portions has it?*

Parietal and visceral.

35 *What* (2) *layers has it?*

Fibrous and serous.

36 *With what is the fibrous layer connected above?*

The deep cervical fascia.

37 *What is the general shape of the pericardium?*

Pyramidal.

38 *Which direction does its apex point?*

Upward.

39 *To what is it attached below?*

The diaphragm.

40 *To what is it attached above?*

The great vessels.

41 *To what is it attached in front?*

The sternum.

42 *By what?*

The sterno-pericardiac ligaments.

43 *How many of these ligaments are there?*

Two.

44 *What are they called?*

The superior and the inferior.

45 *Where is the vestigial fold of the pericardium?*

Between the left pulmonary artery and the left pulmonary vein.

46 *What does it contain?*

The remains of the left superior vena cava.

47 *What* (2) *vessels have complete pericardial coverings?*

The aorta and the pulmonary artery.

48 *Which vessel has no pericardial covering?*

The inferior vena cava.

49 *What* (5) *structures are in relation anteriorly with the pericardium?*

The thymus gland, sterno-pericardiac ligaments, triangularis sterni muscle, internal mammary vessels, and sternum.

50 *What* (4) *structures posteriorly?*

The bronchi, œsophagus, aorta, and pneumogastric nerves.

51 *What* (3) *structures laterally?*

The lungs, pleuræ, and phrenic nerves.

52 *What is the general shape of the heart?*

Conical.

53 *Which way does its apex point?*

Downward and to the left.

54 *Which side of the heart is in front?*

The right.

55 *Which forms the apex beat?*

The left ventricle.

56 *Opposite what* (3) *vertebræ does the base lie?*

The sixth, seventh, and eighth thoracic.

57 *How do you mark on the chest wall the area occupied by the heart?*

The *base* lies under a transverse line on the sternum at the level of the third costal cartilage, half an inch to the right and one inch to the left of the sternum. The *apex* lies under the fifth interspace, two inches below and one inch to the sternal side of the nipple. The *lower border* is indicated by a line curving downward drawn from the apex to the junction of the sixth right costal cartilage with the sternum. Curved lines connecting the line of the base with that of the lower border will complete the outline.

58 *What groove separates the auricles from the ventricles?*

The auriculo-ventricular.

59 *What groove separates the ventricles?*

The interventricular.

60 *What is the course of the blood from the venæ cavæ to the aorta?*

Right auricle, right ventricle, pulmonary artery, lungs, pulmonary veins, left auricle, left ventricle.

61 *Of what* (2) *portions does the right auricle consist?*

The atrium and the auricular appendix.

62 *What vessel does its appendix overlap?*

The aorta.

63 *What are the* (5) *openings into the right auricle?*

The superior vena cava, inferior vena cava, coronary sinus, foramina of Thebesius, and auriculo-ventricular.

64 *Of what are the foramina Thebesii the mouths?*

Small veins from the heart muscle.

65 *Where does the coronary sinus empty?*

Between the inferior cava and the auriculo-ventricular opening.

66 *What valve guards it?*

The coronary valve.

67 *What are the* (5) *elevations in the right auricle?*

The musculi pectinati, Eustachian valve, tubercle of Lower, coronary valve, and annulus ovalis.

68 *In what two places are the musculi pectinati found?*

The anterior wall and the auricular appendix.

69 *Where is the Eustachian valve located?*

Between the annulus ovalis and the auricular wall.

70 *What is its function in the fœtus?*

To direct the blood through the foramen ovale.

71 *To what is its left cornu attached?*

The annulus ovalis.

72 *What does this annulus surround?*

The fossa ovalis.

73 *Of what is the fossa a remnant?*
The foramen ovale.
74 *Where is the tubercle of Lower located?*
Between the openings of the two cavæ.
75 *What valve guards the right auriculo-ventricular opening?*
The tricuspid.
76 *How many leaflets has it?*
Three.
77 *What are their positions?*
One anterior and two posterior.
78 *What elevations are found in the right ventricle?*
The columnæ carneæ.
79 *How many sets are there?*
Three.
80 *How do they differ?*
One set is composed of ridges, a second of bands, and a third of papillæ.
81 *What are the papillæ or those attached by one end called?*
The papillary muscles.
82 *What is attached to the free end of the papillary muscles?*
The chordæ tendineæ.
83 *What other attachments have the chordæ tendineæ?*
To the leaflets of the valves.
84 *In how many places?*
Three.
85 *What are they?*
The base, the middle, and the free edge.

86 *What portion of the right ventricle gives origin to a large artery?*
The infundibulum or conus arteriosus.
87 *What artery?*
The pulmonary.
88 *What valve guards its opening?*
The pulmonary valve.
89 *How many leaflets has it?*
Three.
90 *What is their shape?*
Semilunar.
91 *What are their positions?*
One anterior and two posterior.
92 *What sinus lies behind each?*
The sinus of Valsalva.
93 *What nodule caps each?*
The corpus Arantii.
94 *What bands pass laterally from each nodule?*
The lunulæ.
95 *Into what does the pulmonary artery divide?*
Right and left.
96 *Which passes under the aortic arch?*
The right.
97 *How does the blood get back from the lungs?*
By the pulmonary veins.
98 *How many are there?*
Four.
99 *Do they have valves?*
No.

100 *Of what portions does the left auricle consist?*

The atrium and the auricular appendix.

101 *What does its appendix overlap?*

The pulmonary artery.

102 *What valve guards the left auriculo-ventricular opening?*

The bicuspid or mitral.

103 *How many leaflets has it?*

Two.

104 *What are their positions?*

One is in front and to the right; the other behind and to the left.

105 *What vessel arises from the left ventricle?*

The aorta.

106 *What valve guards its opening?*

The aortic.

107 *How many leaflets has it?*

Three.

108 *What are their positions?*

Two in front and one behind.

109 *In other respects what valve do they resemble?*

The pulmonary.

110 *What is the blood supply of the heart?*

The two coronary arteries.

111 *Between what structures does the right coronary pass?*

The pulmonary artery and the right auricular appendix.

112 *What groove does it traverse?*

The auriculo-ventricular.

113 *Which surface of the heart does it reach?*
The posterior.
114 *What are its terminal branches?*
One which passes on in the same groove and an interventricular branch.
115 *What course do they pursue?*
They occupy the auriculo-ventricular and interventricular grooves.
116 *Between what structures does the left coronary pass?*
The pulmonary artery and the left auricular appendix.
117 *What groove does it occupy?*
The auriculo-ventricular.
118 *Which surface of the heart does it reach?*
The anterior.
119 *What are its terminal branches?*
The same as the right.
120 *What course do they pursue?*
The same relatively as the right.
121 *What is the nerve supply of the heart?*
The superficial and deep cardiac plexuses.
122 *Where is the superficial located?*
Beneath the arch of the aorta.
123 *What nerves form it?*
The superior cervical cardiac branch of the left sympathetic and the inferior cervical cardiac branch of the left pneumogastric.
124 *Where is the deep plexus located?*
Behind the aortic arch and in front of the bifurcation of the trachea.

125 *What nerves form it?*

The other cardiac nerves.

126 *What is the order of the valves of the heart from the surface in?*

Pulmonary, aortic, tricuspid, and mitral.

127 *What point on the surface corresponds to* (a) *the pulmonary valve?* (b) *To the aortic?* (c) *To the tricuspid?* (d) *To the mitral?*

(a) The junction of the third left costal cartilage with the sternum. (b) The third interspace at the left margin of the sternum. (c) The middle of the sternum at the level of the fourth costal cartilage. (d) The third intercostal space an inch to the left of the sternum.

The Fœtal Circulation.

128 *How does the blood get from the placenta to the fœtus?*

Through the umbilical vein.

129 *After passing through the umbilicus, to what fissure of the liver does the vein pass?*

The longitudinal.

130 *What two courses does the blood then take?*

Through the liver and through the ductus venosus.

131 *What* (2) *vessels are connected by the ductus venosus?*

The umbilical vein and the inferior vena cava.

132 *What vessel does the blood then reach?*

The inferior vena cava.

133 *What cavity of the heart does it enter?*

The right auricle.

134 *Through what opening does it pass?*

The foramen ovale.

135 *What directs it thus?*

The Eustachian valve.

136 *After reaching the left auricle, what cavity does it enter?*

The left ventricle.

137 *What vessel does it then enter?*

The aorta.

138 *What part of the body does it supply?*

The head and upper extremities.

139 *On its return what vessel does it reach?*

The superior vena cava.

140 *What cavity of the heart does it enter?*

The right auricle.

141 *Through what opening does it pass?*

The tricuspid.

142 *To reach what cavity?*

The right ventricle.

143 *What vessel does it enter?*

The pulmonary artery.

144 *Where does a little of the blood go?*

To the lungs.

145 *Through what does the major portion of the blood pass?*

The ductus arteriosus.

146 *To get into what vessel?*
The aorta.
147 *To what portion of the body does it go?*
To the trunk and lower extremities.
148 *Into what vessels does some of it pass?*
The hypogastric arteries.
149 *What do these arteries become at the umbilicus?*
The umbilical arteries.
150 *Where do they then carry the blood?*
To the placenta.

The Arch of the Aorta.

151 *What is the first portion of the aorta called? The second part? The third part?*
The arch. The thoracic aorta. The abdominal aorta.
152 *What vessel corresponds to a sacral and coccygeal aorta?*
The arteria sacra media.
153 *Where does the arch of the aorta begin?*
At the left ventricle.
154 *Where does it terminate?*
At the lower border of the fifth thoracic vertebra.
155 *What* (3) *portions has it? Which portion gives off no branches?*
Ascending, transverse, and descending. The descending.
156 *How far does the ascending portion rise?*

To the upper border of the second right costal cartilage.

157 *What are its relations?*

In front, the right auricular appendix, pulmonary artery, thymus gland, and lung. Behind, the left auricle, right bronchus, and right pulmonary artery. On the right, the right auricle and superior vena cava. On the left, the pulmonary artery.

158 *How far does the transverse portion go?*

To the left side of the body of the fourth thoracic vertebra.

159 *What* (3) *structures pass under it?*

The left bronchus, the right pulmonary artery, and the left recurrent laryngeal nerve.

160 *What are its relations?*

In front, the right and left pleuræ and lungs, phrenic and pneumogastric nerves, cardiac branches of the pneumogastric and sympathetic nerves, and the left superior intercostal vein. Behind, the trachea, œsophagus, thoracic duct, and left recurrent laryngeal nerve. Above, its three branches and the left innominate vein. Below, the bifurcation of the pulmonary artery, the left bronchus, the left recurrent laryngeal nerve, the remains of the ductus arteriosus, and the superficial cardiac plexus.

161 *What are its* (3) *branches?*

The innominate, left common carotid, and left subclavian.

162 *What constriction is met with in the descending portion?*

The aortic isthmus.

163 *What dilation is there below this constriction?*

The aortic spindle.

164 *What are the relations of this portion?*

In front, the root of the left lung. Behind, the pleura and the bodies of the fourth and fifth thoracic vertebræ. To the right, the œsophagus, thoracic duct, and the fourth and fifth thoracic vertebræ. To the left, the left lung.

165 *Of what is the thyroidea ima a branch?*

The innominate.

The Thoracic Aorta.

166 *Where does the thoracic aorta begin?*

At the lower border of the fifth thoracic vertebra.

167 *Where does it terminate?*

At the body of the twelfth thoracic vertebra.

168 *In which mediastinum is it found?*

The posterior.

169 *What relation does it bear to the median line?*

It lies to the left of the median line.

170 *What* (3) *relations does the œsophagus bear to it?*

The œsophagus lies first to the right, then in front, and finally to the left.

171 *What are the* (5) *branches of the thoracic aorta?*

The pericardiac, œsophageal, bronchial, mediastinal, and intercostal.

172 *How many pericardiac branches are there? What do they supply?*

Two or three. The pericardium.

173 *What is the function of the bronchial arteries?*

To supply blood for the nutrition of the lungs.

174 *How do they differ from the pulmonary?*

The pulmonary arteries supply blood to be aërated by the lungs.

175 *Of what are they a constituent?*

The roots of the lungs.

176 *How many œsophageal arteries are there? What do they supply?*

Four or five. The œsophagus.

177 *How many intercostal arteries are there?*

Ten pairs.

178 *Those of which side are the longer?*

The right.

179 *What is the tenth intercostal called?*

The subcostal.

180 *Into what branches does each intercostal divide near the vertebræ?*

Anterior and posterior.

181 *Into what does the posterior branch divide?*

A spinal and a muscular branch.

182 *On what muscle does the anterior branch first lie.*

The external intercostal.

183 *Between what muscles does it then lie?*

The external and internal intercostals.

184 *What relation does it bear to the accompanying vein and nerve?*

It lies between them.

The Œsophagus.

185 *Where does the œsophagus begin?*

At the fifth cervical intervertebral disc.

186 *Where does it end?*

At the tenth thoracic vertebra.

187 *Which is the narrowest portion?*

Its upper end.

188 *In which mediastina is it?*

The superior and the posterior.

189 *What plexus surrounds it?*

The œsophageal plexus.

190 *What nerves form this plexus?*

The two pneumogastrics.

191 *What* (3) *relations does the œsophagus bear to the thoracic aorta?*

First to the right, then in front, and finally to the left.

The Thoracic Portion of the Gangliated Cord.

192 *How many pairs of sympathetic ganglia are found in the thorax?*

Twelve.

193 *How are they connected with the spinal nerves?*

By gray and white rami communicantes.

194 *What does the gray ramus do when it reaches the spinal nerve?*

It divides.

195 *What course do these branches pursue?*

One passes up to the spinal cord and the other passes out with the nerve.

196 *What is the course of the white ramus?*

It passes to the ganglion, and either stops there or passes on through succeeding ganglia.

197 *What* (2) *branches does each ganglion have?*

External and internal.

198 *What are the external branches?*

The rami communicantes.

199 *What* (3) *structures are supplied by the internal branches of the four upper ganglia?*

The aorta, mediastinum, and lungs.

200 *What* (3) *nerves arise from the lower eight ganglia?*

The three splanchnic nerves.

201 *How are they named?*

The great, the lesser, and the least.

202 *From what ganglia does the great splanchnic come?*

The fifth to the ninth inclusive.

203 *How does it get into the abdomen?*

Through the crus of the diaphragm.

204 *What does it enter?*
The semilunar ganglion.
205 *From what ganglia does the lesser splanchric come?*
The tenth and eleventh.
206 *How does it get into the abdomen?*
Through the crus of the diaphragm or through the internal arcuate ligament.
207 *What* (2) *plexuses does it enter?*
The solar and the renal.
208 *From what ganglion does the least splanchnic come?*
The twelfth.
209 *How does it get into the abdomen?*
Through the internal arcuate ligament.
210 *What plexus does it enter?*
The renal.

The Azygos Veins.

211 *How many azygos veins are there?*
Three.
212 *What are they called?*
Vena azygos major, vena azygos minor, and vena azygos tertia.
213 *Where does the vena azygos major begin?*
At the right side of the second lumbar vertebra.
214 *Of what fœtal vein is it a remnant?*
The primitive cardinal vein.
215 *How does it get into the thorax?*

Through the aortic opening in the diaphragm.

216 *On which side of the body does it lie?*

The right.

217 *In which mediastinum does it lie?*

The posterior.

218 *Over what does it arch?*

The root of the right lung.

219 *Where does it empty?*

The superior vena cava.

220 *Where does the vena azygos minor begin?*

At the left side of the second lumbar vertebra.

221 *How does it get into the thorax?*

By piercing the left crus of the diaphragm.

222 *How high in the thorax does it rise?*

As high as the eighth thoracic vertebra.

223 *Where does it empty?*

Into the vena azygos major.

224 *In which mediastinum does the vena azygos tertia lie?*

The posterior.

225 *To what vertebræ does it lie adjacent?*

The left side of the fifth, sixth, and seventh thoracic.

226 *Where does it empty?*

Above into the lower left superior intercostal vein and below into the vena azygos major or minor.

The Thoracic Duct.

227 *Where does the thoracic duct begin?*

Opposite the first or second lumbar vertebræ.

228 *In what?*

The receptaculum chyli.

229 *How does it get into the thorax?*

Through the aortic opening of the diaphragm.

230 *On which side of the median line does it lie?*

The left.

231 *Which mediastina does it occupy?*

The posterior and the superior.

232 *What relation does it bear to the aortic arch?*

It passes behind the aortic arch.

233 *How high in the neck does it rise?*

As high as the seventh cervical vertebra.

234 *Over what* (2) *structures does it arch?*

The apex of the left pleura and the left subclavian artery.

235 *Where does it empty?*

Into the junction of the left internal jugular and subclavian veins.

The Diaphragm.

236 *What is the sternal origin of the diaphragm?*

The ensiform cartilage.

237 *What is its costal origin?*

The six lower ribs.

238 *What is its vertebral origin?*

The internal and external arcuate ligaments and the crura.

239 *Which crus is the longer?*

The right.

240 *What is its origin?*

The bodies of the first, second, third, and fourth lumbar vertebræ.

241 *What is the origin of the left crus?*

The bodies of the first, second, and third lumbar vertebræ.

242 *What* (2) *structures pierce the left crus?*

The great splanchnic nerve and the vena azygos minor.

243 *What pierces the right crus?*

The great splanchnic nerve.

244 *What* (4) *structures are in relation with the upper surface of the diaphragm?*

The pleura, pericardium, heart, and lungs.

245 *What* (7) *structures with the lower surface?*

The peritoneum, liver, stomach, spleen, pancreas, kidneys, and suprarenal capsules.

246 *What are the* (3) *openings in the diaphragm?*

The aortic, œsophageal, and caval.

247 *What* (3) *structures pass through the aortic opening?*

The aorta, vena azygos major, and thoracic duct.

248 *What* (3) *through the œsophageal?*

The œsophagus, pneumogastric nerves, and œsophageal branches of the thoracic aorta.

249 *What through the caval?*

The inferior vena cava.

Inguinal Hernia.

250 *What is the inguinal canal?*

A weak spot in the abdominal walls, formed by the descent of the testicle.

251 *How long is it?*

About an inch and a half.

252 *What is its external opening?*

The external abdominal ring.

253 *What is its internal opening?*

The internal abdominal ring.

254 *In what is the external abdominal ring an aperture?*

The aponeurosis of the external oblique.

255 *In what is the internal ring an aperture?*

The transversalis fascia.

256 *How is the external ring bounded:* (a) *Above?* (b) *Below?* (c) *Externally?* (d) *Internally?*

(a) The intercolumnar fibres. (b) The crest of the pubes. (c) Poupart's ligament. (d) The inner pillar.

257 *What fascia is attached to its edges?*
The intercolumnar.

258 *What is the difference between the intercolumnar fascia and the intercolumnar fibres?*
The fascia fills in the ring and the fibres lie above and connect the pillars of the ring.

259 *How is the internal ring bounded:* (a) *Supero-externally?* (b) *Infero-internally?*
(a) By the arching fibres of the transversalis. (b) By the deep epigastric artery.

260 *What fascia fills it in?*
The infundibuliform.

261 *Of what is this fascia a process?*
The transversalis fascia.

262 *What is the third fascia of the spermatic cord?*
The cremasteric.

263 *Of what is it a process?*
The internal oblique.

264 *Where do the cremaster fibres arise?*
From Poupart's ligament.

265 *Where do they insert?*
The spine and crest of the pubes and the infundibuliform fascia.

266 *What is their nerve supply?*
The genital branch of the genito-crural.

267 *What* (2) *structures bound the inguinal canal above.*
The arching fibres of the internal oblique and transversalis.

268 *Where do the arching fibres of the transversalis arise?*

From the outer third of Poupart's ligament.

269 *Where do those of the internal oblique arise?*

From the outer half of Poupart's ligament.

270 *Where do they both insert? As what?*

Into the ilio-pectineal line. As the conjoined tendon.

271 *What relation does the conjoined tendon bear to the external ring?*

It lies behind the ring.

272 *What is interposed between the conjoined tendon and the external ring?*

The triangular ligament.

273 *Of what is it a process?*

Gimbernat's ligament.

274 *What is Gimbernat's ligament?*

A reflection of Poupart's ligament to the ilio-pectineal line.

275 *What is Poupart's ligament?*

A bundle of fibres of the external oblique passing from the anterior superior iliac spine to the spine of the pubes.

276 *How is the inguinal canal bounded below?*

By Poupart's ligament and the transversalis fascia.

277 *What* (2) *structures bound it in front?*

The external and internal oblique.

278 *What* (3) *structures bound it behind?*

The conjoined tendon, the triangular ligament, and the transversalis fascia.

279 *What are the two common forms of inguinal hernia?*

Oblique or indirect and direct.

280 *What are the two varieties of the oblique form?*

Complete and incomplete.

281 *In what does their difference consist?*

Whether or not the gut passes through the external abdominal ring.

282 *What separates the neck of an oblique from that of a direct hernia?*

The deep epigastric artery.

283 *What is an internal inguinal hernia? An external?*

A direct. An indirect.

284 *Why are they so called?*

On account of their piercing the abdominal wall internal or external to the deep epigastric artery.

285 *Which form passes through Hesselbach's triangle?*

The direct.

286 *How is this triangle bounded?*

By Poupart's ligament, the deep epigastric artery, and the outer margin of the rectus abdominis.

287 *What are the coverings of a complete oblique inguinal hernia?*

Skin, superficial fascia, intercolumnar fas-

cia, cremaster muscle, infundibuliform fascia, subperitoneal tissue, and peritoneum.

288 *What are the coverings of an incomplete oblique?*

Skin, superficial fascia, external oblique, cremaster muscle, infundibuliform fascia, subperitoneal tissue, and peritoneum.

289 *What are the coverings of a direct?*

Skin, superficial fascia, intercolumnar fascia, conjoined tendon, transversalis fascia, subperitoneal tissue, and peritoneum.

290 *What are the three fascias of the spermatic cord?*

Intercolumnar, cremasteric, and infundibuliform.

291 *Of what are they processes?*

The intercolumnar of the external oblique aponeurosis; the cremasteric of the internal oblique muscle; the infundibuliform of the transversalis fascia.

292 *What are the* (2) *nerves of the cord?*

The ilio-inguinal and genito-crural.

293 *What are the* (3) *arteries of the cord?*

The spermatic, cremasteric, and artery to the vas deferens.

294 *Of what are they branches?*

The spermatic of the aorta; the cremasteric of the deep epigastric; the artery of the vas deferens of the superior vesical.

295 *What is the venous plexus of the cord?*

The pampiniform.

296 *Where does the left spermatic vein empty?*

Into the renal.

297 *Where does the right empty?*

Into the inferior vena cava.

298 *What is the duct of the cord?*

The vas deferens.

The Common Iliac Artery.

299 *Where does the abdominal aorta divide?*

At the lower border of the fourth lumbar vertebra.

300 *What are its terminal branches?*

The common iliacs.

301 *Into what do they divide? Where?*

The external and internal iliac. At the sacro-iliac junction.

302 *Into what does the internal iliac divide? Where?*

The anterior and posterior trunks. At the upper margin of the great sacro-sciatic foramen.

The Abdominal Aorta.

303 *What are the* (8) *branches of the abdominal aorta?*

The phrenic, cœliac axis, supra-renal, renal, superior mesenteric, spermatic (or ovarian), inferior mesenteric, and lumbar.

The Phrenic Arteries.

304 *What do the phrenic arteries supply?*
The diaphragm.

The Cœliac Axis.

305 *What surrounds the cœliac axis?*
The solar plexus.
306 *What are the* (3) *branches of the cœliac axis?*
The gastric, hepatic, and splenic.
307 *Where does the gastric artery run?*
Along the lesser curvature of the stomach.
308 *Between the layers of what?*
The lesser omentum.
309 *What are its* (4) *branches?*
The œsophageal, cardiac, gastric, and hepatic.
310 *With what does it anastomose?*
The pyloric.
311 *What does the hepatic artery help to bound?*
The foramen of Winslow.
312 *What* (2) *boundaries does it enter?*
The anterior and inferior.
313 *Between the layers of what structure does it pass?*
The lesser omentum.
314 *To which margin of this structure does it lie close?*

The right or free margin.

315 *With what* (2) *other structures does it here lie in relation?*

The portal vein and the common bile duct.

316 *What relation do these structures bear to each other?*

The duct lies to the right, the artery to the left, and the vein between and behind.

317 *What fissure of the liver does the artery reach?*

The transverse.

318 *What are the* (3) *branches of the hepatic artery?*

The pyloric, cystic, and gastro-duodenal.

319 *With what does the pyloric anastomose? Where?*

The gastric. Along the lesser curvature of the stomach.

320 *Between what two layers?*

The layers of the lesser omentum.

321 *What does the cystic supply?*

The gall-bladder.

322 *Into what does the gastro-duodenal divide?*

The superior pancreatico-duodenal and the gastro-epiploica dextra.

323 *What does the superior pancreatico-duodenal supply?*

The pancreas and the upper part of the duodenum.

324 *With what does the gastro-epiploica dextra anastomose? Where?*

The gastro-epiploica sinistra. Along the greater curvature of the stomach.

325 *Between the layers of what?*

The great omentum.

326 *Where is the splenic artery found?*

Along the upper border of the pancreas.

327 *What ligament does it enter?*

The phreno-splenic.

328 *What are its* (4) *branches?*

The pancreaticæ parvæ, pancreatica magna, vasa brevia, and gastro-epiploica sinistra.

329 *With what does the gastro-epiploica sinistra anastomose?*

The gastro-epiploica dextra.

330 *What do the vasa brevia supply?*

The fundus of the stomach.

331 *Between the layers of what structure do they pass?*

The gastro-splenic omentum.

332 *What* (5) *vessels comprise the arterial collar of the stomach?*

The gastric, pyloric, vasa brevia, and gastro-epiploica dextra and sinistra.

The Superior Mesenteric Artery.

333 *Between what viscera does the superior mesenteric artery pass?*

The pancreas and duodenum.

334 *What are its* (5) *branches?*

Inferior pancreatico-duodenal, vasa intestini tenuis, ileo-colic, colica dextra, and colica media.

335 *What does the inferior pancreatico-duodenal supply?*

The pancreas and lower part of the duodenum.

336 *What* (2) *vessels supply the duodenum?*

The superior and inferior pancreatico-duodenal.

337 *What do the vasa intestini tenuis supply?*

The jejunum and upper part of the ileum.

338 *Between the layers of what do they run?*

The mesentery.

339 *What does the ileo-colic supply?*

The lower part of the ileum and the cæcum.

340 *What does the colica dextra supply?*

The ascending colon.

341 *Between what* (2) *layers does it pass?*

The ascending meso-colon.

342 *What does the colica media supply?*

The transverse colon.

343 *Between what* (2) *layers does it pass?*

The transverse meso-colon.

344 *What* (4) *arteries supply the small intestines?*

The superior and inferior pancreatico-duodenal, vasa intestini tenuis, and ileo-colic.

345 *Of what are they branches?*

The first of gastro-duodenal and the others of the superior mesenteric.

The Inferior Mesenteric Artery.

346 *Between the layers of what structure does the inferior mesenteric artery pass?*

The meso-rectum.

347 *What are its* (3) *branches?*

The colica sinistra, sigmoid, and superior hemorrhoidal.

348 *What does the colica sinistra supply?*

The descending colon.

349 *Between the layers of what does it pass?*

The descending meso-colon.

350 *What does the sigmoid artery supply?*

The omega loop.

351 *Between the layers of what does it pass?*

The meso-sigmoid.

352 *What does the superior hemorrhoidal supply?*

The upper part of the rectum.

353 *What* (8) *arteries supply the large intestine?*

The ileo-colic, colica dextra, colica media, colica sinistra, sigmoid, and superior, middle, and inferior hemorrhoidal.

354 *Of what are they branches?*

The first three of the superior mesenteric; the next three of the inferior mesenteric; the middle hemorrhoidal of the anterior

trunk of the internal iliac; the inferior hemorrhoidal of the internal pudic.

The Renal Arteries.

355 *Which renal artery is the longer?*
The right.
356 *What relation does it bear to the inferior cava?*
It passes behind the cava.
357 *Which renal vein is the longer?*
The left.
358 *What relation does it bear to the aorta?*
It passes in front of the aorta.
359 *What important vein empties into the left renal?*
The spermatic.

The Spermatic Arteries.

360 *How do the spermatic arteries get out of the abdomen?*
Through the inguinal canal.
361 *What portion of the gut crosses the left spermatic? The right?*
The omega loop. The ileum.
362 *What do they cross?*
The ureter and the external iliac artery.

The Ovarian Arteries.

363 *Between the layers of what does the ovarian artery pass?*

The broad ligament.

364 *What relation does it bear to the Fallopian tube?*

It lies below the tube.

365 *With what does it anastomose?*

The uterine artery.

The Arteria Sacra Media.

366 *What is the course of the sacra media?*

Down the middle of the sacrum and coccyx.

367 *In what does it terminate?*

Luschka's gland.

The Posterior Trunk of the Internal Iliac.

368 *What are the* (3) *branches of the posterior trunk of the internal iliac?*

The ilio-lumbar, lateral sacral, and gluteal.

The Ilio-lumbar Artery.

369 *Between what structures does the ilio-lumbar run at first?*

The lumbo-sacral cord and the obturator nerve.

370 *Then between what two?*

The psoas magnus and the vertebral column.

371 *What are its terminal branches?*
The iliac branch and the lumbar branch.

The Lateral Sacral Arteries.

372 *How many lateral sacral arteries are there?*
Two.
373 *What are they called?*
The superior and the inferior.

The Gluteal Artery.

374 *What is the gluteal artery sometimes called?*
The superior gluteal.
375 *How does it escape from the pelvis?*
Through the great sacro-sciatic foramen.
376 *What passes out with it?*
The superior gluteal nerve.

The Anterior Trunk of the Internal Iliac.

377 *What are the* (7) *branches of the anterior trunk of the internal iliac?*
The superior, middle, and inferior vesical, middle hemorrhoidal, obturator, sciatic, and internal pudic.
378 *What* (2) *other branches are given off in the female?*
The uterine and vaginal.

379 *What are the terminal branches?*
The sciatic and internal pudic.
380 *What branch to the spermatic cord does the superior vesical give off?*
The artery to the vas deferens.
381 *What duct crosses the obturator artery?*
The vas deferens.
382 *How does the obturator artery escape from the pelvis?*
Through the obturator foramen.
383 *What does it surround?*
The obturator foramen.

The Sciatic Artery.

384 *How does the sciatic artery escape from the pelvis?*
Through the great sacro-sciatic foramen.
385 *In what relation to the pyriformis?*
Below.
386 *What are its* (5) *branches?*
The coccygeal, muscular, articular, inferior gluteal, and comes nervi ischiadici.
387 *What* (4) *vessels form the crucial anastomosis?*
The sciatic, internal and external circumflex, and superior perforating.

The Internal Pudic Artery.

388 *How does the internal pudic escape from the pelvis?*

Through the great sacro-sciatic foramen.

389 *What accompanies it?*

The internal pudic nerve.

390 *What does it wind around?*

The spine of the ischium.

391 *What does it enter?*

The lesser sacro-sciatic foramen.

392 *What muscle passes through this foramen?*

The obturator.

393 *What fossa does the artery then enter?*

The ischio-rectal.

394 *Which wall of the fossa?*

The outer wall.

395 *What canal does it enter?*

Alcock's.

396 *In what fascia is this canal?*

The obturator fascia.

397 *Between what structures does it then pass?*

The two layers of the triangular ligament.

398 *What* (3) *branches does it here give off?*

The artery of the bulb, the artery of the corpus cavernosum, and the dorsal artery of the penis.

399 *Which of these are terminal branches?*

The artery of the corpus cavernosum and the dorsal artery of the penis.

400 *What* (3) *other branches does it give off?*

The inferior hemorrhoidal and the superficial and transverse perineal.

401 *Of what are the* (3) *hemorrhoidal arteries branches?*

The superior is a branch of the inferior mesenteric; the middle of the anterior trunk of the internal iliac; the inferior of the internal pudic.

402 *What other artery supplies the rectum?*

The sacra media.

403 *What is Abernethy's fascia?*

A layer of subperitoneal tissue covering the external iliac artery.

The External Iliac Artery.

404 *What portion of the intestine crosses the right common iliac artery? The left?*

The ileum. The omega loop.

405 *What nerve crosses the external iliac?*

The genito-crural.

406 *What* (2) *ducts?*

The ureter and the vas deferens.

407 *What vessels?*

The ovarian and superior mesenteric.

408 *What does the external iliac become? Where?*

The femoral. At Poupart's ligament.

409 *What are its* (2) *branches?*

The deep circumflex iliac and deep epigastric.

410 *What is the course of the deep circumflex iliac?*

It passes out along Poupart's ligament

and pierces the transversalis, between which and the internal oblique it terminates.

The Deep Epigastric Artery.

411 *What ring does the deep epigastric help to bound?*

The internal abdominal.

412 *What structure winds around it in the male? The female?*

The vas deferens. The round ligament.

413 *What relation does it bear to the external abdominal ring?*

It lies above and to the outer side of the ring.

414 *What triangle does it help to bound?*

Hesselbach's.

415 *Over what fold does it pass?*

The semilunar fold of Douglas.

416 *What branch to the spermatic cord does it give off?*

The cremasteric.

417 *With what does it anastomose? Where?*

The superior epigastric? In the sheath of the rectus.

The Stomach.

418 *What is the left end of the stomach called?*

The fundus.

419 *What is the right end called?*

The pylorus.

420 *What dilatation is there at the pyloric end?*

The pyloric antrum.

421 *What* (2) *curvatures has the stomach?*

The superior or lesser and the inferior or greater.

422 *What is attached to the lesser curvature?*

The lesser omentum.

423 *What is attached to the greater curvature?*

The great omentum.

424 *What is attached to the fundus?*

The gastro-splenic omentum.

425 *With what* (3) *structures is the stomach in relation above?*

The diaphragm, liver, and lesser omentum.

426 *With what* (3) *in front?*

The diaphragm, liver, and abdominal walls.

427 *With what* (3) *below?*

The great omentum, transverse colon, and gastro-splenic omentum.

428 *With what* (7) *behind?*

The spleen, pancreas, left kidney and capsule, great vessels, solar plexus, and crura of the diaphragm.

The Small Intestine.

429 *What* (2) *portions comprise the intestine?*

The large and small intestine.

430 *Which is the longer?*
The small intestine.
431 *Which is the wider?*
The large intestine.
432 *How long is the small intestine?*
About twenty-four feet.
433 *How many portions has the small intestine?*
Three.
434 *What are they?*
The duodenum, jejunum, and ileum.

The Duodenum.

435 *How long is the duodenum?*
About ten inches.
436 *How many portions has it?*
Four.
437 *What are they?*
Ascending, descending, transverse, and ascending.
438 *How far does the first ascending portion rise?*
To the gall-bladder.
439 *How long is it?*
Two inches.
440 *How low does the descending portion go?*
To the third lumbar vertebra.
441 *How long is it?*
Three inches.
442 *What is the course of the transverse portion?*

Across to the left side of the vertebral column.

443 *How long is it?*

Five inches.

444 *How long is the second ascending portion?*

One inch.

445 *Which is the widest portion?*

The first.

446 *What are its* (2) *relations above?*

The liver and gall-bladder.

447 *What* (1) *below?*

The pancreas.

448 *What* (2) *behind?*

The hepatic vessels and common bile duct.

449 *What does the first portion help to bound?*

The foramen of Winslow.

450 *Which is the only portion of the duodenum completely covered with peritoneum?*

The first.

451 *How much of the second, third, and fourth portions is thus covered?*

The anterior surface.

452 *What* (2) *relations has the descending portion in front?*

The transverse colon and meso-colon.

453 *What* (2) *on the left side?*

The pancreas and bile duct.

454 *What* (3) *behind?*

The right kidney and its vessels and the inferior vena cava.

455 *What* (2) *structures empty into the second portion?*

The biliary and pancreatic ducts.

456 *What* (2) *relations has the transverse portion in front?*

The lower layer of the transverse mesocolon and the superior mesenteric vessels.

457 *What* (2) *above?*

The pancreas and the superior mesenteric vessels.

458 *What* (2) *behind?*

The great vessels and the crura of the diaphragm.

459 *What holds the fourth portion in place?*

The musculus suspensorius duodeni.

460 *What peritoneal pouch is found here?*

The fossa duodeno-jejunalis.

The Jejunum and Ileum.

461 *How long is the jejunum?*

About nine feet.

462 *How long is the ileum?*

About fourteen feet.

463 *What holds them in place?*

The mesentery.

464 *What is sometimes found on the ileum?*

Meckel's diverticulum.

465 *Where is it found?*

One to three feet above the cæcum.

466 *Of what is it a remnant?*
The vitello-intestinal duct.

The Large Intestine.

467 *What are the* (5) *differences between large and small intestine?*
The large intestine is wider, shorter, and sacculated; has epiploic appendages and has an interrupted longitudinal muscular coat.
468 *How is the longitudinal muscular coat of the large intestine arranged?*
In three bands.
469 *Where are those bands situated?*
One anterior, one posterior, and one internal.
470 *What effect has this arrangement?*
As the longitudinal bands are shorter than the gut, these bands have a "puckering-string" effect, and hence the sacculations of the large gut.
471 *How long is the large intestine?*
About four and a half feet.
472 *What relation does it bear to the small intestine?*
It surrounds the small intestine.
473 *What are the* (4) *portions of the large intestine?*
Cæcum, colon, omega loop, and rectum.

The Cæcum.

474 *What is the cæcum?*

That portion of the large intestine below the entrance of the ileum.

475 *How long is it?*

About two and a half inches.

476 *What relation does the peritoneum bear to it?*

It is completely surrounded by peritoneum.

477 *What is attached to its lower end?*

The vermiform appendix.

The Vermiform Appendix.

478 *What is the vermiform appendix?*

The undeveloped end of the cæcum.

479 *How long is it?*

About four inches.

480 *How many types are there of cæcum and appendix?*

Four.

481 *Describe one.*

The fœtal type. The cæcum is conical and tapers off to the appendix.

482 *Describe the second.*

The appendix comes off at the apex of the cæcum between two equal sized sacculations.

483 *Describe the third.*

The inner sacculation is smaller than the outer, and the appendix comes off between them at the inner side of the cæcum.

484 *Describe the fourth.*

There is absence of the inner sacculation,

and the appendix comes off at the angle between the outer sacculation and the ileum.

485 *What holds the appendix in place?*

The meso-appendix.

486 *Of what is this a process?*

The left layer of the mesentery.

487 *What runs between its layers?*

The appendicular artery.

488 *Of what is this a branch?*

The ileo-colic.

489 *What* (2) *peritoneal fossæ are found in this region?*

The superior and inferior ileo-cæcal.

The Colon.

490 *What portion of the large intestine follows the cæcum?*

The colon.

491 *How many portions has the colon?*

Three.

492 *What are they?*

The ascending, transverse, and descending.

The Ascending Colon.

493 *How far does the ascending colon extend?*

To the under surface of the liver.

494 *What relation does it bear to the peritoneum?*

It is covered by the latter on its front and sides.

495 *What holds it in place?*

The ascending meso-colon.

496 *What* (3) *relations has the ascending colon posteriorly?*

The right kidney, duodenum, and quadratus lumborum.

497 *What* (1) *internally?*

The small intestine.

498 *What flexure separates the ascending from the transverse colon?*

The hepatic.

The Transverse Colon.

499 *How far does the transverse colon extend?*

To the spleen.

500 *Which way does it bend?*

Downward and forward.

501 *How far down may the loop go?*

To the pubes.

502 *What* (4) *relations has the transverse colon above?*

The liver, gall-bladder, stomach, and spleen.

503 *What* (1) *behind?*

The duodenum.

504 *What* (1) *below?*

The small intestine.

505 *What relation does it bear to the peritoneum?*

It is surrounded by the peritoneum.

506 *What holds it in place?*

The transverse meso-colon.

The Descending Colon.

507 *How far does the descending colon extend?*

To the outer border of the psoas.

508 *What sustains it above?*

The costo-colic ligament.

509 *What flexure connects it with the transverse colon?*

The splenic.

510 *What relation does it bear to the peritoneum?*

The latter covers its front and sides.

511 *What holds it in place?*

The descending meso-colon.

512 *What* (3) *relations has it behind?*

The diaphragm, left kidney, and quadratus lumborum.

513 *What* (1) *in front and internally?*

The small intestine.

The Omega Loop.

514 *Where does the omega loop begin?*

At the outer margin of the psoas.

515 *Where does it terminate?*

At the third piece of the sacrum.

516 *What course does it pursue?*

Across the psoas, down the left pelvic wall, then across to the right, then back toward the left to end in the rectum.

517 *What holds it in place?*

The meso-sigmoid.

518 *What peritoneal pouch is found in relation with the omega loop?*

The inter-sigmoid.

The Rectum.

519 *How many portions has the rectum?*

Two.

520 *What is their extent?*

From the third piece of the sacrum to the tip of the coccyx. From the tip of the coccyx to the anus.

521 *What portion is in relation with the peritoneum?*

The first.

522 *What is the relation?*

The upper portion is covered on its anterior surface.

523 *What* (2) *relations has the first portion posteriorly?*

The sacrum and coccyx.

524 *What* (3) *anteriorly in the male?*

The bladder, prostate gland, and seminal vesicles.

525 *Which* (2) *anteriorly in the female?*

The vagina and uterus.

526 *What surrounds the second portion of the rectum?*

The internal sphincter.

527 *In what* (3) *portions of the gut are found aggregations of circular muscle fibre?*

At the pylorus, the ileo-cæcal valve, and the internal sphincter of the anus.

528 *What is attached to the side of the second portion of the rectum?*

The levator ani muscle.

529 *What is at the end of the rectum?*

The external sphincter.

530 *What are the* (3) *muscles at the anus?*

The internal and external sphincters and the levator ani.

The Liver.

531 *What are the* (5) *lobes of the liver?*

The right, left, caudate, quadrate, and Spigelian.

532 *What are the* (5) *ligaments of the liver?*

The right and left lateral, coronary, falciform, and round.

533 *What is the round ligament?*

The obliterated umbilical vein.

534 *Of what are the other ligaments composed?*

Peritoneum.

535 *To what are the lateral and coronary ligaments attached?*

The diaphragm.

536 *To what is the falciform ligament attached?*

The diaphragm and the sheath of the right rectus abdominis.

537 *What runs between its layers?*

The round ligament.

538 *In what fissure is the round ligament found?*

The longitudinal.

539 *What are the* (5) *fissures of the liver?*

The umbilical or longitudinal, the transverse, and the fissures for the gall-bladder, ductus venosus, and inferior vena cava.

540 *How are these fissures arranged?*

To form the letter H.

541 *What is attached to the lips of the transverse fissure?*

The lesser omentum.

542 *What* (3) *surfaces has the liver?*

Superior, inferior, and posterior.

543 *What makes an impression on the superior surface?*

The heart.

544 *What* (2) *relations has this surface?*

The diaphragm and anterior abdominal wall.

545 *What* (4) *relations has the posterior surface?*

The tenth and eleventh thoracic vertebræ, crura of the diaphragm, œsophagus, and great vessels.

546 *What* (5) *relations has the lower surface?*

The colon, duodenum, stomach, right kidney, and gall-bladder.

547 *What* (3) *portions of the liver are uncovered by peritoneum?*

The fissure for the gall-bladder, the transverse fissure, and the posterior surface of the right lobe.

The Portal Vein.

548 *What are the* (2) *afferent vessels of the liver?*

The hepatic artery and the portal vein.

549 *What is their function?*

The hepatic artery brings blood to nourish the liver and the portal vein blood to be acted on by the liver.

550 *What is the efferent vessel?*

The hepatic vein.

551 *How long is the portal vein?*

About three inches.

552 *Where does it begin?*

Behind the head of the pancreas.

553 *How is it formed?*

By the fusion of the superior mesenteric and splenic veins.

554 *What relation does it bear to the duodenum?*

It passes behind the first portion.

555 *What does it enter?*

The lesser omentum.

556 *With what does it lie?*

The hepatic artery and common bile duct.

557 *In what relation to them?*

Between and behind them.

558 *What surrounds them?*

The capsule of Glisson.

559 *What are the tributaries of the portal vein?*

The splenic, superior mesenteric, gastric, pyloric, and cystic.

560 *Where does the inferior mesenteric empty?*

Into the splenic.

561 *Into what does the portal vein divide?*

Right and left.

562 *Where do they pass?*

Into the liver.

The Gall-bladder.

563 *Where is the gall-bladder situated?*

Between the right and quadrate lobes on the under surface of the liver.

564 *Of what* (3) *portions does it consist?*

Fundus, body, and neck.

565 *Which surface is covered with peritoneum?*

The under.

566 *What is the duct of the gall-bladder?*

The cystic duct.

567 *What is the duct of the liver?*
The hepatic duct.
568 *What do these two unite to form?*
The ductus communis choledochus or common bile duct.
569 *Between the layers of what structure does the common bile duct pass?*
The lesser omentum.
570 *Behind what does it pass?*
The duodenum.
571 *Between what does it pass?*
The duodenum and the head of the pancreas.
572 *Where does it empty?*
Into the second portion of the duodenum.
573 *What enlargement has it before it terminates?*
The ampulla of Vater.

The Pancreas.

574 *Of what* (3) *portions does the pancreas consist?*
Head, body, and tail.
575 *What surrounds the head?*
The duodenum.
576 *How far over does the tail extend?*
To the spleen.
577 *What are the* (3) *relations of the pancreas above?*
The first part of the duodenum, the splenic artery and vein, and the cœliac axis.

578 *What* (2) *below?*

The transverse portion of the duodenum and superior mesenteric vessels.

579 *What* (2) *in front?*

The stomach and transverse meso-colon.

580 *What* (6) *behind?*

The common bile duct, great vessels, superior mesenteric vessels, crura of the diaphragm, left kidney, and spleen.

581 *Where does the duct of the pancreas empty?*

Into the second part of the duodenum.

The Spleen.

582 *Where is the spleen situated?*

In the axillary line opposite the ninth, tenth, and eleventh ribs.

583 *What* (4) *structures are interposed between it and the ribs?*

Peritoneum, diaphragm, pleura, and lung.

584 *What is the fissure of the spleen called?*

The hilum.

585 *What is attached to the edges of the hilum?*

The gastro-splenic omentum.

586 *What other peritoneal structure is attached to the spleen?*

The phreno-splenic ligament.

587 *What are the* (5) *relations of the spleen?*

The stomach, pancreas, left kidney, colon, and diaphragm.

The Peritoneum.

588 *What is the peritoneum?*

A closed serous sac, covering to a greater or less extent the abdominal viscera and lining the abdominal parietes.

589 *What exception is there to the fact that it is a closed cavity?*

In the female the fimbriated end of the oviduct opens into it.

590 *Of what* (2) *folds does it consist?*

The greater and the lesser.

591 *Of what* (2) *cavities does it consist?*

The greater and the lesser.

592 *How do these communicate?*

Through the foramen of Winslow.

593 *How is this foramen bounded?*

In front by the free border of the lesser omentum. Above by the caudate lobe of the liver. Behind by the vena cava. Below by the duodenum and the hepatic vessels.

594 *In what* (2) *ways may the course of the peritoneum be traced?*

Longitudinally and transversely.

595 *In tracing longitudinally, how many folds or layers start at the transverse fissure of the liver?*

Two.

596 *What are they?*

The greater and lesser folds.

597 *Which is anterior?*

The greater.

598 *Where does it pass from the liver?*

To the lesser curvature of the stomach.

599 *Of what does it form the anterior layer?*

The gastro-hepatic omentum.

600 *Where does it pass from the lesser curvature of the stomach?*

Over the anterior surface of the stomach to the greater curvature.

601 *Where does it pass from the greater curvature?*

Down in front of the transverse colon and small intestines to the lower part of the abdomen, where it turns on itself and passes up in front of and then above the transverse colon to reach the posterior abdominal wall.

602 *What does it thus form?*

The outer layers of the great omentum.

603 *What does it include?*

Similar layers of the lesser fold.

604 *After reaching the posterior abdominal wall, what course does it pursue?*

It passes forward and around the transverse colon and returns to the vertebral column.

605 *What does it thus form?*

The transverse meso-colon.

606 *Where does it then go?*

Forward, around the small intestine, and back to the vertebral column again.

607 *What does it thus form?*

The mesentery.

608 *What course does it then pursue?*

It goes down into the pelvis to cover in the upper part of the rectum.

609 *Where does it then go?*

In the male to the bladder, forming the recto-vesical pouch; in the female to the uterus, forming the recto-uterine pouch or pouch of Douglas.

610 *After reaching the uterus, where does it go?*

Over the posterior surface, fundus, and anterior surface of the uterus, and then to the bladder, forming the vesico-uterine pouch.

611 *How much of the bladder is covered in?*

The posterior and upper surfaces.

612 *Where does the peritoneum pass after leaving the bladder?*

Up the anterior abdominal wall, covering the urachus and obliterated hypogastric arteries, to reach the under surface of the diaphragm.

613 *On reaching the diaphragm, where does it go?*

It covers the under surface of the diaphragm and is then reflected to the upper surface of the liver, whence it passes around the anterior edge to the under surface, to

reach the transverse fissure, the starting-point.

614 *What is the posterior of the two layers at the transverse fissure of the liver?*

The lesser fold.

615 *Where does it go after leaving the transverse fissure?*

To the lesser curvature of the stomach.

616 *What does it thereby form?*

The posterior layer of the gastro-hepatic omentum.

617 *Where does it then go?*

It covers the posterior surface of the stomach and reaches the greater curvature.

618 *Where does it then pass?*

Down to the lower part of the abdominal cavity and back inside of similar layers of the greater fold.

619 *What does it thus form part of?*

The great omentum.

620 *After this, where does it pass?*

Above the transverse colon and back to the vertebral column.

621 *Where does it then go?*

Up the vertebral column to the diaphragm, whence it passes to the liver, to finally reach the transverse fissure.

622 *In what* (2) *situations is the peritoneum traced transversely?*

Above and below the transverse colon.

623 *In starting from the median line anteriorly and passing to the right* ***above*** *the*

transverse colon, what is the first structure enclosed?

The round ligament of the liver.

624 *What ligament is formed by including the round ligament?*

The falciform.

625 *Where does the peritoneum then go?*

Around the lateral abdominal wall to the posterior wall and across the great vessels and vertebral column to the left side.

626 *Where does it then pass?*

To the spleen.

627 *From the spleen where does it go?*

To the fundus of the stomach, forming the posterior layer of the gastro-splenic omentum.

628 *After reaching the stomach, where does it go?*

It covers the under surface of the stomach, and, on reaching the pyloric end, passes over to the right to surround the hepatic artery, portal vein, and common bile duct, after which it returns to the pylorus.

629 *What does it form by including the hepatic vessels?*

The free border of the gastro-hepatic omentum.

630 *After returning to the pylorus, where does it go?*

Over the anterior surface of the stomach to the fundus and then to the spleen,

forming the anterior layer of the gastro-splenic omentum.

631 *Where does it then go?*

Completely around the spleen and back to the abdominal wall, around which it passes to the starting-point, the middle line.

632 *Beginning at the anterior median line and passing to the right* ***below*** *the transverse colon, what is its course?*

It passes around the abdominal walls to reach the ascending colon, the sides and front of which it covers.

633 *What does it thus form?*

The ascending meso-colon.

634 *Where does it then pass?*

To the vertebral column, whence it goes forward, surrounds the small intestine, and returns to the vertebral column, forming the mesentery.

635 *Where does it then go?*

To the left as far as the descending colon, the sides and front of which it covers to form the descending meso-colon.

636 *What does it then do?*

It passes around the lateral wall to the starting-point, the middle line.

The Great Omentum.

637 *What are the* (3) *omenta?*

The gastro-colic or greater, the gastro-hepatic or lesser, and the gastro-splenic.

638 *To what is the great omentum attached above?*

The stomach and transverse colon.

639 *Of how many layers does it consist:* (a) *Above the transverse colon?* (b) *Below the transverse colon?*

(a) Two. (b) Four.

640 *How far down does it go?*

Usually to the pubes.

641 *What* (2) *arteries run between its layers at the greater curvature of the stomach?*

The gastro-epiploica dextra and sinistra.

The Lesser Omentum.

642 *To what is the lesser omentum attached:* (a) *Above?* (b) *Below?* (c) *At the left?*

(a) The lips of the transverse fissure of the liver. (b) The lesser curvature of the stomach. (c) The œsophagus.

643 *Which border is free?*

The right.

644 *What does it contain?*

The hepatic artery, portal vein, and common bile duct.

645 *Of what does it form the anterior boundary?*

The foramen of Winslow.

646 *What* (2) *vessels run between its layers at the lesser curvature of the stomach?*

The gastric and pyloric arteries.

The Gastro-splenic Omentum.

647 *What are the* (2) *attachments of the gastro-splenic omentum?*

The fundus of the stomach and the lips of the spleen.

648 *Of how many layers is it composed?*

Two.

649 *What* (2) *structures are found between its layers?*

The splenic artery and the vasa brevia.

The Mesentery.

650 *What holds the small intestine in place?*

The mesentery.

651 *How many layers has it?*

Two.

652 *What structures are found between them?*

Vessels, nerves, and lymphatic vessels and glands.

653 *What is its posterior attachment?*

The vertebral column from the left side of the second lumbar vertebra to the right sacro-iliac synchondrosis.

The Meso-colon.

654 *What structures hold the large intestine in place?*

The ascending, transverse, and descending meso-colons and the meso-sigmoid.

655 *What are found between their layers?*
Vessels, nerves, and lymphatics.
656 *With one exception, of how many layers are they composed?*
Two.
657 *What is the exception?*
The transverse meso-colon, which consists of four layers.

The Pelvic Fascia.

658 *With what is the pelvic fascia continuous above?*
The iliac and transversalis fascias.
659 *Where does it divide?*
At the arcus tendineus or "white line."
660 *Into what?*
The obturator and recto-vesical fascias.
661 *What process does the obturator fascia give off?*
The ischio-rectal or anal fascia.
662 *What relation does the anal fascia bear to the levator ani?*
It covers the outer surface of the levator ani.
663 *What space does it help to bound?*
The ischio-rectal fossa.
664 *What covers the inner surface of the levator ani?*
The recto-vesical fascia.
665 *What are the* (2) *portions of the obturator fascia?*

That covering the obturator internus above the white line and that below.

666 *What are they called?*

The upper portion is called the pelvic portion and the lower portion the ischio-rectal portion.

667 *What canal is there in the ischio-rectal portion?*

Alcock's.

668 *What does it contain?*

The internal pudic vessels and nerve.

669 *What fossa does this portion of the obturator fascia line?*

The ischio-rectal.

The Ischio-rectal Fossa.

670 *Where is the ischio-rectal fossa?*

At the side of the rectum.

671 *How is it bounded externally?*

The obturator fascia below the white line, the ischio-rectal portion of the obturator fascia, and the innominate bone.

672 *How is it bounded internally?*

The levator ani and coccygeus muscles and the ischio-rectal fascia.

The Perineum.

673 *What line divides the perineum into two portions?*

A line connecting the tuberosities of the ischium.

674 *What is the anterior portion called?*

The perineum proper or the urethral triangle.

675 *What is the posterior portion called?*

The ischio-rectal region or anal triangle.

676 *Where does the external sphincter of the anus arise?*

From the tip of the coccyx.

677 *What is its insertion?*

The tendinous centre of the perineum.

678 *What other muscles insert here?*

The superficial transversus perinei, the bulbo-cavernosi, and the levatores ani.

679 *How many layers of superficial perineal fascia are there?*

Two, superficial and deep.

680 *Which one covers the whole perineum?*

The superficial layer.

681 *What is the deep layer called?*

Colles' fascia.

682 *How far back does it pass?*

To the posterior border of the superficial transversus perinei, around which it turns.

683 *To what is it attached?*

The posterior edge of the superficial and deep layers of the triangular ligament.

684 *What are its lateral attachments?*

The ischio-pubic ramus and the ischial tuberosity.

685 *What space lies under it?*

The superficial perineal interspace.

686 *How many of these interspaces are there?*

Two.

687 *What are they called?*

The superficial and deep perineal interspaces.

688 *How is the superficial interspace bounded superficially?*

By Colles' fascia.

689 *How is it bounded deeply?*

By the superficial layer of the triangular ligament.

690 *What are the* (11) *contents of the superficial interspace?*

The crura and bulb of the penis, the superficial transversus perinei, the bulbo-cavernosi and the ischio-cavernosi muscles, the dorsal arteries of the penis, the arteries of the corpora cavernosa and the superficial perineal arteries and associated veins, and the dorsal nerves of the penis.

691 *What is the origin of the superficial transversus perinei?*

The tuberosity and ramus of the ischium.

692 *What is its insertion?*

The central tendon of the perineum.

693 *Where does the ischio-cavernosus arise?*

The tuberosity and ramus of the ischium, the ramus of the pubes, and the root of the crus penis.

694 *Where does it insert?*

The dorsal surface of the corpus cavernosum.

695 *What slip does it give off?*

The compressor venæ dorsalis.

696 *Where does the bulbo-cavernosus arise?*

From a median raphe extending the whole length of the bulb.

697 *Where does it insert?*

The superficial layer of the triangular ligament and the bulb and dorsum of the corpus cavernosum.

698 *How many layers has the triangular ligament?*

Two, superficial and deep.

699 *What is the superficial layer?*

The deep perineal fascia.

700 *What does it separate?*

The two perineal interspaces.

701 *What* (6) *structures pierce it?*

The urethra, the ducts of Cowper's glands, the arteries of the corpora cavernosa, the arteries of the bulb, the dorsal arteries of the penis, and the dorsal nerves of the penis.

702 *What structure runs over its upper margin?*

The dorsal vein of the penis.

703 *How is the deep perineal interspace bounded?*

Superficially by the superficial layer of the triangular ligament and deeply by the deep layer of the triangular ligament.

704 *What are the* (6) *contents of the deep interspace?*

The membranous urethra, Cowper's glands, the deep transversus perinei, the internal pudic arteries giving off their last three branches, the accompanying veins, and the dorsal nerves of the penis.

705 *What is the origin of the deep transversus perinei?*

The inner surface of the ischio-pubic ramus.

706 *What is its insertion?*

A median raphe, the opposite pubic ramus, the bulb and the tissue between the corpora cavernosa.

707 *What is the deep layer of the triangular ligament?*

A prolongation of the obturator fascia across the arch formed by the rami of the pubes and ischium.

708 *What are the* (7) *layers and spaces of the perineum enumerated from the surface in?*

Skin, superficial layer of the superficial fascia, Colles' fascia, superficial interspace, superficial layer of the triangular ligament, deep interspace, deep layer of the triangular ligament.

SECTION III.

The Upper Extremity,

Including the Subclavian Artery.

The Subclavian Artery.

1 *What are the branches of the arch of the aorta?*

The innominate, the left common carotid, and the left subclavian.

2 *Into what does the innominate divide?*

The right subclavian and the right common carotid.

3 *How many innominate veins are there?*

Two.

4 *How are they formed?*

By the junction of the internal jugular and subclavian veins.

5 *What do they unite to form?*

The superior vena cava.

6 *Which is the longer?*

The left.

7 *Which subclavian artery is the longer?*

The left.

8 *How many portions has the subclavian artery?*

Three.

9 *What divides it into three portions?*

The scalenus anticus.

10 *What relation does the subclavian vein bear to it?*

The vein lies in front and below.

11 *What* (2) *structures separate the subclavian artery and vein?*

The scalenus anticus muscle and the phrenic nerve.

12 *How high in the neck does the subclavian artery rise?*

Half an inch above the clavicle.

13 *Over what does it arch?*

The pleura and the first rib.

14 *Between what muscles does it pass?*

The scalenus anticus and the scalenus medius.

15 *What structure winds around the right subclavian artery?*

The right recurrent laryngeal nerve.

16 *What portion gives off no branches?*

The third. Sometimes the suprascapular or the posterior scapular arises from it.

17 *What are the* (3) *branches of the first portion? The branch of the second portion?*

The vertebral, the thyroid axis, and the internal mammary. The superior intercostal.

The Vertebral Artery.

18 *How many portions has the vertebral artery? What are they?*

Four. Cervical, vertebral, occipital, and cranial.

19 *Between what two muscles does the vertebral artery pass?*

The scalenus anticus and the longus colli.

20 *What vertebra does it enter? What protion of the vertebra?*

The sixth cervical. The foramen in the transverse process.

21 *What vertebra does it leave?*

The atlas.

22 *What triangle does it enter?*

The suboccipital.

23 *How is that triangle bounded?*

By the superior oblique, the inferior oblique, and the rectus capitis posticus major.

24 *What forms its floor?*

The posterior occipito-atloid ligament.

25 *What forms its roof?*

The complexus.

26 *What are its* (3) *contents?*

The vertebral artery, the suboccipital nerve, and a plexus of veins.

27 *What does the artery then pierce?*

The posterior occipito-atloid ligament.

28 *How does it get into the cranium?*

Through the foramen magnum.

29 *With what does it anastomose?*

Its fellow of the opposite side.

30 *What is formed thereby?*

The basilar artery.

31 *How does the vertebral vein begin?*

In a plexus of veins.

32 *Where does it begin?*

In the suboccipital triangle.

33 *What relation does it bear to the artery in the vertebræ? After it leaves the vertebræ?*

It surrounds the artery. It lies anterior to it.

34 *Where does it empty?*

Into the innominate vein.

35 *Which portion of the vertebral artery gives off no branches?*

The cervical portion.

36 *What are the* (2) *branches of the second portion?*

Lateral spinal and muscular.

37 *What are the* (2) *branches of the third portion?*

Muscular and anastomatic.

38 *What are the* (4) *branches of the fourth portion?*

Posterior meningeal, anterior spinal, posterior spinal, and posterior inferior cerebellar.

39 *Of what is the anterior meningeal a branch?*

The internal carotid.

40 *Of what is the middle meningeal a branch?*

The internal maxillary.

41 *Of what is the small meningeal a branch?*

The internal maxillary.

42 *Of what is the posterior meningeal a branch?*

The vertebral.

43 *What* (4) *other arteries have meningeal branches?*

The anterior and posterior ethmoidal, the ascending pharyngeal, and the occipital.

44 *What portion of the brain is grooved by the basilar artery?*

The pons.

45 *What are its* (5) *branches?*

The transverse, the internal auditory, the superior cerebellar, the anterior inferior cerebellar, and the posterior cerebral.

46 *What are its terminal branches?*

The posterior cerebrals.

47 *How does the internal auditory escape from the cranium?*

Through the internal auditory meatus.

48 *What* (3) *other structures pass out with it?*

The auditory nerve, the facial nerve, and the pars intermedia of Wrisberg.

The Thyroid Axis.

49 *What are the* (3) *branches of the thyroid axis?*

The inferior thyroid, the suprascapular, and the transversalis colli.

50 *What artery arises from the subclavian opposite to it?*

The internal mammary.

51 *What branch of the axis sometimes arises from the subclavian?*

The suprascapular; and sometimes the posterior scapular branch of the transverse cervical.

The Inferior Thyroid Artery.

52 *What relation does the inferior thyroid bear to the carotid sheath?*

It lies behind the sheath.

53 *What* (2) *other structures bear the same relation?*

The sympathetic and recurrent laryngeal nerves.

54 *With what ganglion of the sympathetic is it in relation?*

The middle cervical.

55 *What is that ganglion sometimes called?*

The thyroid ganglion.

56 *What are the* (5) *branches of the inferior thyroid artery?*

Ascending cervical, inferior laryngeal, tracheal, œsophageal, and muscular.

57 *With what* (3) *arteries does the ascending cervical anastomose?*

Ascending pharyngeal, vertebral, and occipital.

The Suprascapular Artery.

58 *In which triangle is the suprascapular artery found?*

The subclavian.

59 *What relation does it bear to the transverse ligament of the scapula?*

It passes over the ligament.

60 *What passes under the ligament?*

The suprascapular nerve.

61 *To what* (2) *fossæ is it distributed?*

The supraspinous and infraspinous.

62 *With what* (3) *arteries does it anastomose?*

Posterior scapular, subscapular, and dorsal scapular.

The Transversalis Colli Artery.

63 *What* (2) *triangles does the transversalis colli traverse?*

The subclavian and the occipital.

64 *What are its terminal branches?*

The posterior scapular and the superficial cervical.

65 *Which is the continuation of the main trunk?*

The posterior scapular.

66 *With what* (4) *arteries does the posterior scapular anastomose?*

The suprascapular, subscapular, dorsal scapular, and intercostal.

67 *With what does the superficial cervical anastomose?*

The superficial branch of the arteria princeps cervicis.

The Internal Mammary Artery.

68 *What are the* (2) *portions of the internal mammary artery?*

Cervical and thoracic.

69 *Which portion gives off no branches?*

The cervical portion.

70 *What nerve crosses this portion?*

The phrenic.

71 *What are the* (8) *branches of the internal mammary?*

The superior phrenic, mediastinal, pericardiac, sternal, anterior intercostal, perforating, musculo-phrenic, and superior epigastric.

72 *Where does the internal mammary divide into its terminal branches?*

At the sixth interspace.

73 *What are its terminal branches?*

Musculo-phrenic and superior epigastric.

74 *With what does the superior epigastric anastomose? Where?*

The deep epigastric. In the sheath of the rectus abdominis.

75 *How many intercostal spaces are supplied by the anterior intercostal branches?*

The upper five or six.

76 *Which* (3) *perforating arteries supply the mammary gland?*

The second, third, and fourth.

The Superior Intercostal Artery.

77 *From which aspect of the subclavian artery does the superior intercostal arise?*
The posterior.
78 *Behind what muscle?*
The scalenus anticus.
79 *What nerve lies on this muscle?*
The phrenic.
80 *What ganglion is in relation with the superior intercostal artery?*
The first thoracic ganglion.
81 *How many intercostal spaces are supplied by the superior intercostal?*
One and a half.
82 *What other branch does it give off?*
The profunda cervicis.
83 *With what does this branch anastomose?*
The deep branch of the arteria princeps cervicis.

The Axilla.

84 *What does the subclavian artery become?*
The axillary.
85 *Where does it become axillary?*
At the lower border of the first rib.
86 *What is the general shape of the axilla?*
Pyramidal.
87 *Which wall is the wider, the inner or*

the outer? Which is the longer, the anterior or the posterior?

The inner. The posterior.

The Anterior Wall of the Axilla.

88 *What* (3) *structures form the anterior wall of the axilla?*

The pectoralis major and minor and the costo-coracoid membrane.

The Costo-coracoid Membrane.

89 *What is another name for the costo-coracoid membrane?*

The clavi-pectoral fascia.

90 *How many borders has it?*

Four.

91 *Of what is it a portion?*

The deep cervical fascia.

92 *To what is it attached above?*

The clavicle.

93 *By how many lamellæ?*

Two.

94 *What is there between these leaflets?*

The subclavius muscle.

95 *To what* (2) *structures is it attached below?*

The pectoralis minor and the axillary sheath.

96 *What is its external attachment?*

The coracoid process.

97 *What is its internal attachment?*
The cartilage of the first rib.
98 *What* (4) *structures pierce it?*
The cephalic vein, the acromial thoracic artery and vein, and the external anterior thoracic nerve.

The Posterior Wall of the Axilla.

99 *What* (3) *structures form the posterior wall of the axilla?*
The subscapularis, latissimus dorsi and teres major muscles.
100 *What large artery lies on the posterior axillary wall? What nerves?*
The subscapular. The subscapular.

The Quadrilateral Space.

101 *How is the quadrilateral space bounded?*
By the subscapularis, teres major, humerus, and long head of the triceps.
102 *What* (3) *structures pass through it?*
The posterior circumflex artery and vein and the circumflex nerve.

The Triangular Space.

103 *How is the triangular space bounded?*
By the subscapularis, teres major, and long head of the triceps.
104 *What passes through it?*
The dorsalis scapulæ artery.

The External Wall of the Axilla.

105 *What* (3) *structures form the outer wall of the axilla? Which head of the biceps?*

The humerus, coraco-brachialis, and biceps. The short head.

106 *What large artery and vein are on this wall? What nerves?*

The axillary. The brachial plexus.

The Internal Wall of the Axilla.

107 *What* (3) *structures form the inner wall of the axilla?*

The serratus magnus, the first four ribs, and the corresponding intercostal muscles.

108 *What nerve lies on this wall?*

The posterior thoracic.

109 *What* (2) *nerves pierce this wall?*

The intercosto-humeral and the lateral cutaneous branch of the third intercostal.

The Nerve Supply of the Axilla.

110 *What nerves supply the anterior axillary wall? The posterior? The external? The internal?*

The external and internal anterior thoracic. The three subscapular. The musculo-cutaneous. The posterior thoracic and the three upper intercostals.

The Apex and Base of the Axilla.

111 *What* (3) *structures bound the apex of the axilla?*

The clavicle, scapula, and first rib.

112 *What forms the base of the axilla?*

The axillary fascia.

113 *With what is it continuous anteriorly?*

The pectoral fascia.

The Axillary Artery.

114 *What relation does the axillary vein bear to the artery?*

It lies anterior and internal to the artery.

115 *What relation does the brachial plexus bear to the first part of the artery? To the second part?*

It lies above and external to the artery. It surrounds the artery.

116 *What* (2) *nerves lie to the outer side of the third part?* (4) *To the inner side?* (2) *Posterior to it?*

The musculo-cutaneous and the outer head of the median. The ulnar, the internal cutaneous, the lesser internal cutaneous, and the inner head of the median. The musculo-spiral and the circumflex.

117 *How many portions has the axillary artery?*

Three.

118 *What divides it into these portions?*

The pectoralis minor.

119 *Where are these portions located?*

Above, behind, and below the pectoralis minor.

The Superior Thoracic Artery.

120 *What are the* (2) *branches of the first portion?*

The superior thoracic and the acromial thoracic.

121 *Which pierces the costo-coracoid membrane?*

The acromial thoracic.

122 *Which runs along the upper border of the pectoralis minor?*

The superior thoracic.

123 *What artery runs along the lower border?*

The long thoracic.

The Acromial Thoracic Artery.

124 *What are the* (4) *branches of the acromial thoracic?*

Acromial, pectoral, humeral, and clavicular.

125 *In what intermuscular groove is the humeral branch found?*

In the delto-pectoral groove.

126 *What vein is found in this groove?*

The cephalic.

The Alar Thoracic Artery.

127 *What are the* (2) *branches of the second portion of the axillary?*

The alar thoracic and long thoracic.

128 *Which supplies the axillary contents?*

The alar thoracic.

The Long Thoracic Artery.

129 *Where do you find the other branch?*

Along the lower border of the pectoralis minor.

The Subscapular Artery.

130 *What are the* (3) *branches of the third portion?*

Anterior and posterior circumflex and subscapular.

131 *Which is the largest?*

The subscapular.

132 *On which wall of the axilla is it found?*

The posterior.

133 *What nerve accompanies it?*

The long subscapular.

134 *With what* (3) *arteries does it anastomose?*

The posterior scapular, long thoracic, and intercostal.

135 *What* (2) *branches does it give off?*

The dorsal scapular and infrascapular.

136 *Which passes through the triangular space?*
The dorsal scapular.

The Circumflex Arteries.

137 *Opposite what artery is the anterior circumflex given off?*
The posterior circumflex.
138 *What is the crucial anastomosis at the shoulder?*
The acromial thoracic, the anterior and posterior circumflex, and the superior profunda.
139 *Through what space does the posterior circumflex pass?*
The quadrilateral space.
140 *What accompanies it?*
Its vein and the circumflex nerve.

The Brachial Artery.

141 *What does the axillary artery become? Where?*
The brachial. At the teres major.
142 *What* (2) *muscles overlap the brachial?*
The coraco-brachialis and the biceps.
143 *What nerve crosses it? In what direction?*
The median. From without inward.
144 *What vein crosses it at the elbow?*
The median basilic.
145 *What are the* (5) *branches of the brachial?*

The superior profunda, inferior profunda, muscular, nutrient, and anastomotica magna.

146 *What does the superior profunda accompany? The inferior profunda?*

The musculo-spiral nerve. The ulnar nerve.

147 *Which quadrant of the elbow is not supplied by the anastomotica magna?*

The anterior external.

148 *What are the terminal branches of the brachial?*

The radial and ulnar.

149 *Which is the continuation of the main trunk?*

The radial.

150 *Which is the larger branch?*

The ulnar.

The Antecubital Fossa.

151 *How is the antecubital fossa bounded?*

By the supinator longus, the pronator radii teres, and the intercondylar line.

152 *What* (4) *structures form its roof?*

The skin, superficial and deep fascia, and bicipital fascia.

153 *What* (2) *veins are found in its roof? What* (2) *nerves?*

The median cephalic and median basilic. The internal cutaneous and the musculo-cutaneous.

154 *What* (2) *muscles form its floor?*

The brachialis anticus and supinator brevis.

155 *What are its contents? How are they arranged?*

The median nerve, the brachial artery, and the tendon of the biceps. From within outward as enumerated.

The Radial Artery.

156 *Between what muscles does the radial artery lie in the upper third of the forearm? In the lower two-thirds?*

The supinator longus and the pronator radii teres. The supinator longus and the flexor carpi radialis.

157 *What relation does the radial nerve bear to it?*

The nerve lies to the radial side.

158 *How does it reach the back of the hand?*

By passing under the extensor tendons of the thumb; through the "snuff-box."

159 *How does it reach the palm?*

Between the heads of the abductor indicis.

160 *What are its branches in the forearm?*

The radial recurrent, muscular, superficialis volæ, and anterior carpal.

161 *What is the anastomosis in front of the outer condyle?*

The radial recurrent and superior profunda.

162 *With what does the anterior carpal anastomose?*

The anterior ulnar carpal, anterior interosseous, and palmar recurrent.

163 *What does it form thereby?*

The anterior carpal rete.

164 *With what does the superficial volar anastomose?*

The superficial branch of the ulnar.

165 *What does it form thereby?*

The superficial palmar arch.

166 *What are the* (4) *branches of the radial in the wrist?*

Posterior carpal, metacarpal, dorsales pollicis, and dorsalis indicis.

167 *With what does the posterior carpal anastomose?*

The posterior ulnar carpal and the anterior interosseous.

168 *What does it form thereby?*

The posterior carpal arch or rete.

169 *What* (2) *branches does this arch give off?*

The metacarpals.

170 *With what do they anastomose?*

The second and third perforating arteries.

171 *What space does the metacarpal artery supply?*

The second interosseous.

172 *With what does it anastomose?*

The first perforating.

173 *Between what muscles does the radial artery run after reaching the palm?*

The adductor pollicis and the flexor brevis pollicis.

174 *What are the* (5) *branches of the radial in the palm?*

The radialis indicis, princeps pollicis, perforating, recurrent, and interosseous.

175 *Between what muscles do the princeps pollicis and radialis indicis pass?*

The adductor pollicis and the adductor indicis.

176 *How many perforating arteries are there?*

Three.

177 *How do they get to the back of the hand?*

Between the heads of the second, third, and fourth dorsal interosseous muscles.

178 *With what do they anastomose?*

The three metacarpal arteries.

The Ulnar Artery.

179 *What nerve crosses the upper part of the ulnar artery?*

The median.

180 *What muscle separates them?*

The deep head of the pronator radii teres.

181 *Between what muscles does the lower part of the ulnar artery lie?*

The flexor sublimis digitorum and the flexor carpi ulnaris.

182 *What relation does the ulnar nerve bear to it?*

The nerve lies to the ulnar side.

183 *How does it get into the palm?*

Over the annular ligament.

184 *What* (5) *branches does it give off in the forearm?*

Anterior and posterior ulnar recurrent, interosseous, muscular, and nutrient.

185 *What is the anastomosis in front of the inner condyle?*

Anterior ulnar recurrent, inferior profunda, and anastomotica magna.

186 *What is the anastomosis behind the inner condyle?*

Posterior ulnar recurrent, inferior profunda, and anastomotica magna.

187 *Into what does the interosseous divide?*

Anterior and posterior interosseous.

188 *Between what muscles does it pass?*

The flexor longus pollicis and flexor profundus digitorum.

189 *Where does the anterior interosseous lie?*

On the interosseous membrane.

190 *What accompanies it?*

The anterior interosseous nerve.

191 *What branch does it give off?*

The median.

192 *What does the branch accompany?*

The median nerve.

193 *Where does the anterior interosseous terminate?*

At the upper border of the pronator quadratus.

194 *How does the posterior interosseous get to the back of the forearm?*

By passing between the oblique ligament and the interosseous membrane.

195 *Where does it lie?*

Between the superficial and deep extensors.

196 *What does it accompany?*

The posterior interosseous nerve.

197 *What branch does it give off?*

The interosseous recurrent.

198 *What is the anastomosis behind the outer condyle?*

The interosseous recurrent, superior profunda, and anastomotica magna.

199 *What are the* (2) *branches of the ulnar in the wrist?*

The anterior and posterior carpal.

200 *With what do they anastomose?*

Corresponding branches of the radial.

201 *What do they form thereby?*

The anterior and posterior carpal arches.

202 *Into what does the ulnar divide in the palm?*

The superficial and deep.

203 *Which is the direct continuation of the main artery?*

The superficial.

204 *With what does it anastomose?*

The superficial volar.

205 *What does it form thereby?*

The superficial palmar arch.

206 *What* (5) *structures separate it from the deep arch? From the surface?*

Flexor tendons, lumbricales, median and ulnar nerves, and the short muscles of the little finger. Skin, superficial and deep fascia, and palmaris brevis.

207 *What are the* (4) *branches of the superficial arch?*

Four digital arteries.

208 *How many fingers do they supply?*

Three and a half.

209 *On which side of the hand?*

The ulnar.

210 *How are the remaining fingers supplied?*

By the radialis indicis, princeps pollicis, and superficialis volæ.

211 *Between what muscles does the deep branch pass?*

The adductor and flexor brevis minimi digiti.

212 *With what does the deep branch of the ulnar anastomose?*

The radial.

The Brachial Plexus.

213 *What nerves form the brachial plexus?*

The fifth, sixth, seventh, and eighth cervical and first dorsal.

214 *What divisions of these nerves?*

The anterior.

215 *Between what muscles does this plexus emerge?*

The scalenus anticus and medius.

216 *How many stages has the plexus? What are they?*

Four. Nerves, trunks, divisions, and cords.

217 *What are the two sets of branches?*

Those above the clavicle and those below.

218 *What are the* (4) *branches above the clavicle?*

Suprascapular, posterior thoracic, communicating, and muscular.

The Suprascapular Nerve.

219 *What relation does the suprascapular bear to the transverse ligament of the scapula?*

It passes under the ligament.

220 *What* (3) *structures are supplied by it?*

The supraspinatus and infraspinatus muscles and the shoulder joint.

The Posterior Thoracic Nerve.

221 *From what nerves does the posterior thoracic arise?*

The fifth, sixth, and seventh cervical.

222 *In what muscle?*

The scalenus medius.

223 *In what relation to the plexus? To the axillary artery?*

Posterior. Posterior.

224 *On which wall of the axilla is it found?*
The inner.

225 *What does it supply?*
The serratus magnus.

The Communicating Branch.

226 *With what does the communicating branch communicate?*
The phrenic.

The Outer Cord.

227 *What are the* (3) *branches of the outer cord?*
The external anterior thoracic, musculo-cutaneous, and outer head of the median.

The External Anterior Thoracic Nerve.

228 *With what does the external anterior thoracic form a loop?*
The internal anterior thoracic.

229 *What does it pierce?*
The costo-coracoid membrane.

230 *What does it supply?*
The pectoralis major.

The Musculo-cutaneous Nerve.

231 *What does the musculo-cutaneous pierce?*

The coraco-brachialis.

232 *What* (3) *muscles does it supply?*

The biceps, coraco-brachialis, and brachialis anticus.

233 *Between what muscles is it found above the elbow?*

The biceps and brachialis anticus.

234 *Into what does it divide at the elbow?*

An anterior and a posterior branch.

235 *How far do these branches run?*

As far as the thenar eminence.

The Median Nerve.

236 *How many heads has the median nerve?*

Two.

237 *From what do they come?*

The outer and inner cords.

238 *Which crosses the axillary vessels?*

The inner head.

239 *What relation does it bear to the brachial artery?*

First outside, then over, and finally on the inside.

240 *In what part of its course does it give off no branches?*

In the arm.

241 *Between the heads of what muscle does it pass?*

The pronator radii teres.

242 *What separates it from the ulnar artery?*

The deep head of the pronator radii teres.

243 *Between what muscles does it lie in the forearm?*

The flexor sublimis and flexor profundus digitorum.

244 *What accompanies it here?*

The median artery.

245 *Between what muscles does it lie at the wrist?*

The flexor carpi radialis and palmaris longus.

246 *How does it get into the hand?*

Under the annular ligament.

247 *What are the* (3) *branches in the forearm?*

Muscular, anterior interosseous, and palmar cutaneous.

248 *Between what muscles does the palmar cutaneous pass?*

The flexor carpi radialis and palmaris longus.

249 *What fingers in the palm are supplied by the median? What on the dorsum?*

Three and a half on the radial side. The last phalanx of all the fingers and the last two phalanges of the three middle fingers.

The Inner Cord.

250 *What are the* (5) *branches of the inner cord?*

The internal anterior thoracic, lesser internal cutaneous, internal cutaneous, ulnar, and inner head of median.

The Internal Anterior Thoracic Nerve.

251 *Between what vessels does the internal anterior thoracic pass?*

The axillary artery and vein.

252 *What does it pierce?*

The pectoralis minor.

253 *What does it supply?*

The pectoralis minor and major.

The Lesser Internal Cutaneous Nerve.

254 *With what does the lesser internal cutaneous inosculate?*

The intercosto-humeral.

The Internal Cutaneous Nerve.

255 *Into what does the internal cutaneous divide? Where?*

An anterior and a posterior branch. At the elbow.

256 *How far do its branches run?*

As far as the wrist.

The Ulnar Nerve.

257 *Which intermuscular septum does the ulnar nerve pierce?*

The internal.

258 *Between the heads of what muscle does it pass?*

The flexor carpi ulnaris.

259 *Between what muscles does it run?*

The flexor carpi ulnaris and flexor profundus digitorum.

260 *How does it get into the palm?*

Over the annular ligament.

261 *Which part gives off no branches?*

The part in the arm.

262 *What muscle does it supply in the forearm? Half of what muscle?*

Flexor carpi ulnaris. Flexor profundus digitorum.

263 *What fingers does the ulnar supply in the palm? On the dorsum?*

One and a half on the ulnar side. Two and a half on the ulnar side.

The Posterior Cord.

264 *What are the* (3) *branches of the posterior cord?*

The musculo-spiral, circumflex, and subscapular.

The Subscapular Nerves.

265 *How many subscapular nerves are there?*

Three.

266 *What* (4) *structures do they supply?*

The subscapularis, latissimus dorsi and teres major muscles, and the shoulder joint.

The Circumflex Nerve.

267 *How many divisions has the circumflex nerve?*

Two; superior and inferior.

268 *Through what space does it pass?*

The quadrilateral.

269 *What accompanies it?*

The posterior circumflex artery and vein.

270 *What* (2) *muscles does it supply?*

The deltoid and teres minor.

271 *What else does it supply?*

The skin over the deltoid.

The Musculo-spiral Nerve.

272 *What groove does the musculo-spiral occupy?*

The musculo-spiral.

273 *What artery accompanies it?*

The superior profunda.

274 *Between the heads of what muscles does it pass?*

The long and short heads of the triceps.

275 *Which intermuscular septum does it pierce?*

The external.

276 *Between what muscles does it lie above the elbow?*

The brachialis anticus and supinator longus.

277 *What cutaneous branches does it give off?*

External and internal.

278 *How many external? Internal?*

Two. One.

279 *What are the externals called?*

Superior and inferior.

280 *What do they supply?*

The area over the lower part of the biceps and the back of the forearm.

281 *What* (3) *muscles in the arm are supplied by the musculo-spiral?*

The triceps, anconeus, and brachialis anticus.

282 *What are its terminal branches?*

The radial and posterior interosseous.

283 *How does the posterior interosseous get to the back of the forearm?*

By piercing the supinator brevis.

284 *What fingers does the radial supply?*

Three and a half on the dorsum, radial side.

The Cutaneous Nerve Supply.

285 *What is the cutaneous nerve supply of the front of the arm?*

Circumflex, musculo-spiral, intercosto-humeral, and internal cutaneous.

286 *What is the cutaneous nerve supply of the back of the arm?*

Circumflex, musculo-spiral, intercosto-humeral, and lesser internal cutaneous.

287 *What is the cutaneous nerve supply of the front of the forearm?*

Musculo-cutaneous and internal cutaneous.

288 *What is the cutaneous nerve supply of the back of the forearm?*

Musculo-cutaneous, internal cutaneous, and musculo-spiral.

289 *What is the cutaneous nerve supply of the palm of the hand?*

Median, radial, ulnar, and musculo-cutaneous.

290 *What is the cutaneous nerve supply of the dorsum of the hand?*

Median, radial, and ulnar.

The Superficial Veins.

291 *How do the superficial veins of the upper extremity begin?*

In two plexuses.

292 *Where are they located?*

On the dorsum of the hand and the front of the wrist.

293 *What are the* (4) *main veins of the forearm?*

Radial, median, and anterior and posterior ulnar.

294 *Into what does the median divide?*

Median cephalic and median basilic.

295 *With what does the median cephalic unite?*

The radial.

296 *To form what?*

The cephalic.

297 *In what sulcus is the cephalic vein?*

The delto-pectoral.

298 *With what artery?*

The humeral branch of the acromial thoracic.

299 *What structure does it pierce?*

The costo-coracoid membrane.

300 *Where does it empty?*

Into the axillary.

301 *What do the anterior and posterior ulnar veins unite to form?*

The common ulnar.

302 *With what does the common ulnar unite?*

The median basilic.

303 *To form what?*

The basilic.

304 *What does the median basilic cross?*

The brachial artery.

305 *What does the basilic help to form?*

The axillary vein.

The Muscles.

306 *Where does the trapezius arise?*

From the inner third of the superior curved line of the occipital bone, from the

ligamentum nuchæ, and from the spines of the seventh cervical and all the thoracic vertebræ and the supraspinous ligaments.

307 *Where does it insert?*

The outer third of the clavicle, the acromion process, and the spine of the scapula.

308 *Where does the levator anguli scapulæ arise?*

From the transverse processes of the upper four cervical vertebræ.

309 *Where does it insert?*

The upper part of the posterior border of the scapula.

310 *Where does the rhomboideus minor arise?*

From the lower part of the ligamentum nuchæ, the spines of the seventh cervical and first thoracic vertebræ, and the supraspinous ligaments.

311 *Where does it insert?*

The posterior border of the scapula opposite the spine.

312 *Where does the rhomboideus major arise?*

From the spines of the upper four or five thoracic vertebræ and the supraspinous ligaments.

313 *Where does it insert?*

The posterior border of the scapula opposite the infraspinous fossa.

314 *Where does the latissimus dorsi arise?*

From the spines of the lower five or six thoracic vertebræ and the supraspinous ligaments, the lumbar fascia, the outer third of

the iliac crest, the lower three or four ribs, and the inferior angle of the scapula.

315 *Where does it insert?*

The bottom of the bicipital groove.

316 *How many portions has the pectoralis major? What are they?*

Two. Sternal and clavicular.

317 *Where does the sternal portion arise?*

From the sternum as far down as the ensiform cartilage, the cartilages of the second to the sixth ribs, and the aponeurosis of the external oblique.

318 *Where does the clavicular portion arise?*

The inner half of the clavicle.

319 *Where does it insert?*

The external bicipital ridge.

320 *What is peculiar about its insertion?*

Those fibres which arise the highest insert the lowest.

321 *Where does the subclavius arise?*

From the first rib and its cartilage.

322 *Between the layers of what does it lie?*

The costo-coracoid membrane.

323 *Where does it insert?*

On the lower surface of the clavicle.

324 *Where does the pectoralis minor arise?*

From the third, fourth, and fifth ribs and the intervening fascia.

325 *Where does it insert?*

The coracoid process of the scapula.

326 *Where does the serratus magnus arise?*

From the first to the ninth ribs.

327 *Where does it insert?*

Into the posterior margin of the scapula and adjacent portions.

328 *Where does the deltoid arise?*

From the outer third of the clavicle, the acromion process, and the spine of the scapula.

329 *Where does it insert?*

Above the middle of the outer surface of the humerus.

330 *Where does the supraspinatus arise?*

From the supraspinous fossa, the spine of the scapula, and overlying fascia.

331 *Where does it insert?*

Into the greater tuberosity of the humerus.

332 *Where does the infraspinatus arise?*

From the infraspinous fossa, the spine of the scapula, and overlying fascia.

333 *Where does it insert?*

The greater tuberosity of the humerus.

334 *Where does the teres minor arise?*

The upper two-thirds of the axillary border of the infraspinous fossa.

335 *Where does it insert?*

Into the greater tuberosity of the humerus.

336 *Where does the subscapularis arise?*

From the subscapular fossa, the lower two-thirds of the outer border of the scapula, and from intermuscular septa.

337 *Where does it insert?*

The lesser tuberosity of the humerus.

338 *Where does the teres major arise?*

From the lower third of the axillary border of the infraspinous fossa and from intermuscular septa.

339 *Where does it insert?*

The inner lip of the bicipital groove.

340 *Where does the coraco-brachialis arise?*

From the coracoid process and the short head of the biceps.

341 *What nerve pierces it?*

The musculo-cutaneous.

342 *Where does it insert?*

The middle third of the humerus and the inner intermuscular septum.

343 *Where does the biceps arise?*

The short head from the coracoid process and the long head from the upper margin of the glenoid cavity and the glenoid ligament.

344 *Where does it insert?*

The bicipital tubercle of the radius and the deep fascia of the forearm.

345 *Where does the brachialis anticus arise?*

From the lower three-fifths of the front of the humerus and from the external and internal intermuscular septa.

346 *Where does it insert?*

The coronoid process.

347 *Where does the triceps arise?*

The long head from the lower margin of the glenoid cavity and the scapular border

below it, the external head from the humerus above the musculo-spiral groove and the intermuscular septum, and the internal head from the humerus below the musculo-spiral groove and the external and internal intermuscular septa.

348 *Where does it insert?*

The olecranon process and the deep fascia of the forearm.

349 *How many layers of flexor muscles are there in the forearm?*

Four.

350 *Which arise from the inner condyle?*

The first two layers.

351 *Where do the other two layers arise?*

From the radius and ulna.

352 *Where does the pronator radii teres arise?*

From the internal condyle and from the coronoid process.

353 *What passes between its heads?*

The median nerve.

354 *Where does it insert?*

The middle of the outer surface of the radius.

355 *Where does the flexor carpi radialis arise?*

The internal condyle and intermuscular septa.

356 *Where does it insert?*

The base of the second metacarpal bone.

357 *Where does the palmaris longus arise?*

From the internal condyle, deep fascia, and intermuscular septa.

358 *Where does it insert?*

The palmar fascia and annular ligament.

359 *Where does the flexor carpi ulnaris arise?*

One head from the internal condyle and deep fascia and the other head from the olecranon and upper two-thirds of the ulna.

360 *What passes between its heads?*

The ulnar nerve.

361 *Where does it insert?*

The pisiform bone.

362 *Where does the flexor sublimis digitorum arise?*

One head from the internal condyle, intermuscular septum, internal lateral ligament, and the coronoid process; the other head from the oblique line of the radius.

363 *Where does it insert?*

By four tendons, each of which splits to be inserted into the sides of the middle phalanges of the four fingers.

364 *Where does the flexor profundus digitorum arise?*

The upper three-fourths of the ulna and the interosseous membrane.

365 *Where does it insert?*

By four tendons which pass between the slips of the flexor sublimis digitorum and are inserted into the base of the third phalanges of the four fingers.

366 *Where does the flexor longus pollicis arise?*

One head from the radius from the oblique line down, except the lower two inches; the other head from the coronoid process.

367 *Where does it insert?*

The base of the last phalanx of the thumb.

368 *Where does the pronator quadratus arise?*

The lower fourth of the ulna.

369 *Where does it insert?*

The lower two inches of the radius.

370 *Where does the supinator longus arise?*

From the upper two-thirds of the external condylar ridge and the intermuscular septum.

371 *Where does it insert?*

The styloid process of the radius.

372 *Where does the extensor carpi radialis longior arise?*

From the lower third of the external condylar ridge, from the intermuscular septum, and from the common extensor tendon.

373 *Where does it insert?*

The base of the second metacarpal bone.

374 *Where does the extensor carpi radialis brevior arise?*

The common tendon, intermuscular septa, and the external lateral ligament.

375 *Where does it insert?*

The bases of the second and third metacarpal bones.

376 *Where does the extensor communis digitorum arise?*

From the common tendon, the deep fascia, and intermuscular septa.

377 *Where does it insert?*

The lateral ligaments of the metacarpophalangeal joints and the base of the second and third phalanges of the four fingers.

378 *Where does the extensor minimi digiti arise?*

The common tendon, the deep fascia, and intermuscular septa.

379 *Where does it insert?*

With the corresponding tendon of the extensor communis digitorum.

380 *Where does the extensor carpi ulnaris arise?*

One head from the common tendon, the deep fascia, and intermuscular septa; the other head from the ulna and aponeurosis.

381 *Where does it insert?*

The base of the fifth metacarpal bone.

382 *Where does the anconeus arise?*

The external condyle and the posterior ligament of the elbow.

383 *Where does it insert?*

The olecranon and the upper third of the ulna.

384 *Where does the supinator brevis arise?*

From the external condyle, the external lateral and orbicular ligaments, and the ulna.

385 *What nerve pierces it?*

The posterior interosseous.

386 *Where does it insert?*

The neck and that portion of the radius above the oblique line.

387 *Where does the extensor ossis metacarpi pollicis arise?*

The middle of the radius and ulna, the interosseous membrane, and intermuscular septa.

388 *Where does it insert?*

The base of the first metacarpal bone.

389 *Where does the extensor brevis pollicis arise?*

The lower part of the radius, the interosseous membrane, and aponeurosis.

390 *Where does it insert?*

The base of the first phalanx of the thumb.

391 *Where does the extensor longus pollicis arise?*

From the lower half of the ulna and the interosseous membrane.

392 *Where does it insert?*

The base of the last phalanx of the thumb.

393 *Where does the extensor indicis arise?*

From the lower third of the ulna, the

interosseous membrane, and the intermuscular septum.

394 *Where does it insert?*

The first tendon of the extensor communis.

The Palmar Fascia.

395 *With what* (2) *structures is the palmar fascia continuous above?*

The annular ligament and the palmaris longus.

396 *Of what* (3) *divisions does it consist?*

A central and two lateral.

397 *How many processes has the central portion?*

Four.

398 *What structures pass between them?*

The digital arteries and nerves.

399 *What do they bind down?*

The flexor tendons.

400 *What is the outer lateral division called? The inner lateral division?*

The thenar fascia. The hypothenar fascia.

The Muscles.

401 *Where does the palmaris brevis arise?*

From the annular ligament and the palmar fascia.

402 *Where does it insert?*

The skin of the hand at the ulnar border of the palm.

403 *How many lumbricales are there?*

Four.

404 *What is their origin?*

The two outer from the outer side of the first and second tendons of the flexor profundus digitorum and the two inner from the adjacent sides of the second, third, and fourth tendons of the same muscle.

405 *Where do they insert?*

The aponeurosis of the extensor communis tendon on the radial side of each finger.

406 *How many palmar interossei are there?*

Three.

407 *Where do they arise?*

From the mesial side of the second, fourth, and fifth metacarpal bones.

408 *Where do they insert?*

The aponeurosis of the extensor tendons on the back of the first phalanges of the middle, ring, and little fingers and the adjacent portion of the side of the phalanx.

409 *How many dorsal interossei are there?*

Four.

410 *Where do they arise?*

From the five metacarpal bones, each arising by two heads from the adjacent bones.

411 *What is the first called?*

The abductor indicis.

412 *What passes between its heads?*

The radial artery.

413 *What passes between the heads of the other three?*

The three perforating arteries.

414 *Where do they insert?*

Into the aponeurosis of the extensor communis tendons and the base of the first phalanx of the first, second, and third fingers, the second or middle finger receiving the insertion of two.

415 *Where does the abductor pollicis arise?*

The scaphoid bone, the trapezium, the anterior annular ligament, the palmar fascia, and the tendon of the extensor ossis metacarpi pollicis.

416 *Where does it insert?*

The base of the first phalanx of the thumb and the aponeurosis of the extensor longus pollicis.

417 *Where does the opponens pollicis arise?*

The trapezium and the anterior annular ligament.

418 *Where does it insert?*

The whole length of the first metacarpal bone.

419 *Where does the flexor brevis pollicis arise?*

The outer head from the annular ligament and the trapezium; the inner head from the os magnum, the bases of the first, second, and third metacarpal bones, and the sheath of the flexor carpi radialis tendon.

420 *Where does it insert?*

The base of the first phalanx of the thumb.

421 *Where does the adductor pollicis arise?*

From the third metacarpal bone.

422 *Where does it insert?*

The base of the first phalanx of the thumb and the adjacent aponeurosis of the extensor longus pollicis.

423 *Where does the abductor minimi digiti arise?*

The pisiform bone and the tendon of the flexor carpi ulnaris.

424 *Where does it insert?*

The base of the first phalanx of the little finger and the adjacent aponeurosis of the extensor minimi digiti.

425 *Where does the flexor brevis minimi digiti arise?*

The unciform bone and the annular ligament.

426 *Where does it insert?*

The base of the first phalanx of the little finger.

427 *Where does the opponens minimi digiti arise?*

From the unciform bone and annular ligament.

428 *Where does it insert?*

The ulnar border and head of the fifth metacarpal bone.

SECTION IV.

The Lower Extremity.

Poupart's Ligament.

1 *What does the external iliac artery become? Where?*

Femoral. At Poupart's ligament.

2 *What (8) structures pass under Poupart's ligament?*

The femoral artery and vein, psoas and iliacus muscles, and external cutaneous, anterior crural, crural branch of the genito-crural and accessory obturator nerves.

3 *What is Poupart's ligament?*

A bundle of fibres of the aponeurosis of the external oblique, extending from the anterior superior spine of the ilium to the spine of the pubes.

4 *What is Gimbernat's ligament?*

A reflection of Poupart's to the ilio-pectineal line.

5 *What is the triangular ligament?*

A reflection of Gimbernat's to the linea alba.

The Femoral Sheath.

6 *How many compartments has the femoral sheath?*

Three.

7 *What is in the outer compartment? In the middle?*

The artery. The vein.

8 *What is the inner compartment called?*

The femoral canal.

9 *What is its upper opening? Its lower opening?*

The femoral ring. The saphenous opening.

Scarpa's Triangle.

10 *What triangle contains the femoral vessels?*

Scarpa's.

11 *How is it bounded?*

Above by Poupart's ligament, internally by the adductor longus, and externally by the sartorius.

12 *What (5) structures form its floor?*

The psoas, iliacus, pectineus, adductor longus and adductor brevis muscles.

13 *What forms its roof?*

The fascia lata.

The Facia Lata.

14 *What is the fascia lata?*

The deep fascia of the thigh.

15 *What (2) muscles insert into it?*

The gluteus maximus and the tensor fasciæ femoris.

16 *What is the tendon of the tensor fasciæ femoris called?*

The ilio-tibial band.

17 *What are the two portions of the fascia lata?*

The iliac and the pubic.

18 *What relation do they bear to the femoral vessels? What is Hey's ligament?*

The iliac lies in front and the pubic behind the vessels. The upper inner part of the iliac portion.

Femoral Hernia.

19 *What opening is there in the fascia lata?*

The saphenous opening.

20 *What fills it in?*

The cribriform fascia.

21 *What is this a portion of?*

The deep layer of the superficial fascia.

22 *What (3) structures pass through it?*

The long saphenous vein, and the superficial epigastric and superficial external pudic arteries.

23 *How is the femoral ring bounded* (a) *in front?* (b) *Behind?* (c) *Internally?* (d) *Externally?*

(a) Poupart's ligament. (b) the pectineus. (c) Gimbernat's ligament. (d) the sheath of the femoral vein.

24 *What fills in the femoral ring?*

The septum crurale.

25 *What are the coverings of a femoral hernia?*

Skin, superficial fascia, cribriform fascia,

femoral sheath, septum crurale, subperitoneal fat and peritoneum.

The Common Femoral Artery.

26 *What relation does the common femoral vein bear to the artery?*

The vein is internal to the artery.

27 *What muscle separates the common femoral artery from the hip-joint?*

The psoas magnus.

28 *What are the (4) branches of the common femoral artery?*

The superficial epigastric, superficial external pudic, deep external pudic and superficial circumflex iliac.

29 *Which (2) pass through the saphenous opening?*

The superficial epigastric and superficial external pudic.

30 *Which crosses the pectineus muscle?*

The deep external pudic.

31 *What does the common femoral artery divide into?*

The superficial femoral and the deep femoral or profunda femoris.

32 *What (3) relations does the profunda bear to the superficial?*

First external, then behind, finally internal.

The Deep Femoral Artery.

33 *What are the (5) branches of the profunda?*

The external and internal circumflex and the three perforating.

34 *What is the termination of the profunda called?*

The fourth perforating.

35 *Which perforating artery enters into the anostomosis at the knee?*

The fourth.

36 *Which enters into the crucial anastomosis?*

The first.

37 *What are the (3) branches of the external circumflex?*

Ascending, transverse and descending.

38 *Under what muscle does the ascending pass?*

The tensor fasciæ femoris.

39 *Under what muscle does the descending branch pass?*

The rectus femoris.

40 *Into what anastomosis does it enter?*

The anastomosis at the knee.

41 *Into what anastomosis does the transverse branch enter?*

The crucial.

42 *How are the perforating arteries named?*

First, second and third or superior, middle and inferior.

43 *What muscle do they all perforate?*

The adductor magnus.

44 *What relation do they bear to the adductor brevis?*

The first is above, the second passes through and the third below.

45 *Between what muscles does the internal circumflex pass?*

The psoas and the pectineus.

46 *Between what second pair?*

The quadratus femoris and the adductor magnus.

47 *What anastomosis does it enter?*

The crucial.

Hunter's Canal.

48 *What nerve crosses the superficial femoral artery at the apex of Scarpa's triangle?*

The internal cutaneous.

49 *What then does the artery enter?*

Hunter's canal.

50 *Where does this canal begin?*

At the apex of Scarpa's triangle.

51 *Where does it terminate?*

At the opening in the adductor magnus.

52 *How is it bounded internally? Externally?*

The adductor longus and magnus. The vastus internus.

53 *What forms its roof?*

Aponeurosis.

54 *What muscle overlies the roof?*

The sartorius.

55 *What (3) structures are found in the canal?*

The superficial femoral artery and vein and the long saphenous nerve.

56 *What relation does the vein bear to the artery?*

The vein lies external.

57 *How does the nerve escape from the canal?*

By piercing the roof.

58 *What artery escapes in a similar manner?*

The anastomotica magna.

59 *How do the superficial femoral artery and vein escape from the canal?*

By passing through the adductor magnus.

The Popliteal Space.

60 *What do they then become?*

The popliteal.

61 *What space do they enter?*

The popliteal space.

62 *What is the shape of the space?*

Lozenge or diamond shaped.

63 *How is it bounded* (a) *supero-externally?* (b) *Supero-internally?* (c) *Infero-externally?* (d) *Infero-internally?*

(a) By the biceps. (b) By the inner hamstrings (semi-tendinosus, semi-membranosus, sartorius and gracilis). (c) By the plantaris and the outer head of the gastrocnemius. (d) By the inner head of the gastrocnemius.

64 *What (4) structures form its floor?*

The femur, tibia, posterior ligament of Winslow and popliteus muscle.

65 *What forms its roof?*

The deep fascia.

66 *What structure pierces its roof?*

The short saphenous vein.

67 *What (2) nerves are found in the superficial popliteal fascia?*

The small sciatic and the internal cutaneous.

68 *How many popliteal nerves are there?*

Two, internal and external.

69 *Which is in relation with the artery?*

The internal.

70 *What (3) relations does it bear to the artery?*

Outside, behind, inside.

71 *What (3) relations does the vein bear to the artery?*

Outside, behind, inside.

72 *What small nerve lies on the artery?*

The geniculate branch of the obturator.

73 *How does it get into the joint?*

By piercing the posterior ligament.

74 *What else enters the joint in a similar manner?*

The azygos articular artery.

75 *What are (7) the branches of the popliteal artery?*

The superior external and internal articular, inferior external and internal articular, azygos articular, superior and inferior muscular.

76 *What (3) arteries from the thigh enter the circumpatellar anastomosis?*

The external circumflex, fourth perforating and anastomotica magna.

77 *What (8) arteries comprise this anastomosis?*

The superior external and internal articular, inferior external and internal articular, external circumflex, fourth perforating, anastomotica magna and anterior tibial recurrent.

78 *Into what does the popliteal artery divide? Where?*

The anterior and posterior tibial. At the lower border of the popliteus muscle.

The Anterior Tibial Artery.

79 *How does the anterior tibial get to the front of the leg?*

By passing over the interosseous membrane and between the heads of the tibialis posticus.

80 *Between what muscles does it lie in the upper third? In the middle third? In the lower third?*

The tibialis anticus and extensor longus digitorum. The tibialis anticus and extensor longus hallucis. The extensor longus hallucis and extensor longus digitorum.

81 *What relation does the nerve bear to it in the upper third? In the middle third? In the lower third?*

The nerve lies outside. In front. Outside or in front.

82 *What are its (6) branches?*

The anterior and posterior tibial recur-

rent, superior fibular, muscular, and internal and external malleolar.

83 *What tendon crosses it?*

The extensor proprius hallucis.

The Dorsalis Pedis Artery.

84 *What does it become? Where?*

The dorsalis pedis. At the ankle.

85 *What tendon crosses the dorsalis pedis?*

The inner tendon of the extensor brevis digitorum.

86 *What are its (4) branches?*

The tarsal, metatarsal, dorsalis hallucis, and communicating.

87 *What are the branches of the metatarsal?*

The three digital.

88 *How many toes do they supply?*

Three and a half on the fibular side.

89 *What are the terminal branches of the dorsalis pedis?*

The dorsalis hallucis and communicating.

90 *Which goes to the sole of the foot?*

The communicating.

91 *How does it get there?*

By passing between the heads of the first dorsal interosseous muscle.

92 *With what does it anastomose?*

The external plantar.

93 *What is formed thereby?*

The plantar arch.

94 *Into how many branches does the dorsalis hallucis break up?*

Two.

95 *Which is crossed by a tendon? What tendon?*

The inner. The extensor proprius hallucis.

96 *How many toes are supplied by the dorsalis hallucis?*

One and a half on the tibial side.

The Posterior Tibial Artery.

97 *Where does the posterior tibial artery begin?*

At the lower border of the popliteus muscle.

98 *What relation does it bear to the two layers of muscles in the leg?*

It lies between them and under the deep transverse fascia.

99 *What are its (5) branches?*

The peroneal, muscular, nutrient, communicating and internal calcanean.

100 *What are (5) the branches of the peroneal?*

The anterior peroneal, muscular, nutrient, communicating and external calcanean.

101 *Into what does the posterior tibial divide?*

The internal and external plantar.

102 *Where does this division take place?*

Under the internal annular ligament.

103 *Under what muscle does this bifurcation take place?*

The abductor hallucis.

104 *At which malleolus?*

The inner.

105 *Which plantar artery is the larger?*

The external.

106 *Between what (2) structures does it first lie?*

The calcaneum and abductor hallucis.

107 *Between what (2) muscles does it then pass?*

The abductor minimi digiti and flexor brevis digitorum.

108 *How many toes does it supply?*

Three and a half on the fibular side.

109 *What perforating branches does it give off?*

Two sets, anterior and posterior.

110 *How many posterior are there?*

Three.

111 *How do they get to the dorsum of the foot?*

Between the heads of the three outer dorsal interosseous muscles.

112 *With what do they anastomose?*

The digital or interosseous branches of the metatarsal.

113 *How many anterior perforating arteries are there?*

Four.

114 *How do they reach the dorsum of the foot?*

By passing through the distal part of the interosseous spaces.

115 *With what do they antastomose?*
The interosseous branches of the metatarsal.

The Lumbar Plexus.

116 *What nerves form the lumbar plexus?*
The last thoracic and the first four lumbar.
117 *In what muscle is this plexus formed?*
The psoas magnus.
118 *What are its (7) branches?*
The ilio-hypogastric, ilio-inguinal, genito-crural, anterior crural, obturator, accessory obturator and external cutaneous.
119 *What (2) nerves cross the quadratus lumborum?*
The ilio-hypogastric and ilio-inguinal.

The Ilio-hypogastric Nerve.

120 *What muscle does the ilio-hypogastric then pierce?*
The transversalis.
121 *Into what does it divide?*
An iliac and a hypogastric branch.
122 *What does the iliac branch pierce?*
The internal and external oblique muscles.
123 *What area does it supply?*
The skin of the gluteal region as far down as the great trochanter.
124 *What does the hypogastric branch pierce?*
The internal oblique muscle.

125 *With what does it inosculate?*
The ilio-inguinal.
126 *What does it then pierce? Where?*
The external oblique muscle. An inch above the external abdominal ring.
127 *What area does it supply?*
The hypogastric.

The Ilio-Inguinal Nerve.

128 *What does the ilio-inguinal pierce?*
The transversalis muscle.
129 *With what does it communicate?*
The ilio-hypogastric nerve.
130 *What does it then pierce?*
The internal oblique muscle.
131 *What does it then pass through?*
The external abdominal ring.
132 *What area does it supply?*
The skin of the external genitals and the upper inner part of the thigh.

The Genito-Crural Nerve.

133 *On what muscle does the genito-crural lie?*
The psoas magnus.
134 *On what artery does it lie?*
The external iliac.
135 *Into what does it divide?*
A genital and a crural branch.
136 *How does the genital branch escape from the abdomen?*
Through the external abdominal ring.

137 *What does it supply?*

The cremaster muscle.

138 *How does the crural branch get out of the abdomen?*

Beneath Poupart's ligament.

139 *What does it supply?*

The skin of the upper front part of the thigh.

The Obturator Nerve.

140 *How does the obturator nerve escape from the abdomen?*

Through the obturator foramen.

141 *What accompanies it?*

The obturator artery and vein.

142 *Into how many divisions does it break up?*

Two.

143 *What are they called?*

Anterior and posterior.

144 *What separates them?*

The adductor brevis muscle.

145 *What relation does the anterior branch bear to the obturator externus? The posterior?*

It lies in front of the muscle. It pierces the muscle.

146 *What are the (6) branches of the anterior division?*

To the hip-joint, adductor longus, adductor brevis, gracilis and pectineus muscles and a cutaneous branch.

147 *What are the (4) branches of the posterior division?*

To the hip-joint, adductor magnus and ob-

turator externus muscles and the geniculate branch.

148 *How does the geniculate branch get to the back of the thigh?*

By piercing the adductor magnus.

149 *What space does it enter?*

The popliteal.

150 *What artery does it lie on?*

The popliteal.

151 *How does it get into the joint?*

By piercing the posterior ligament.

The Accessory Obturator Nerve.

152 *How does the accessory obturator nerve escape from the abdomen?*

Beneath Poupart's ligament.

153 *What does it supply?*

The hip-joint and the pectineus muscle.

The External Cutaneous Nerve.

154 *How does the external cutaneous nerve escape from the abdomen?*

Beneath Poupart's ligament.

155 *What are its branches?*

Anterior and posterior.

156 *How far down does it go?*

To the knee.

The Anterior Crural Nerve.

157 *How does the anterior crural nerve escape from the abdomen?*

Beneath Poupart's ligament.

158 *In what intermuscular groove does it lie?*

A groove between the psoas and iliacus.

159 *What relation does it bear to the femoral sheath?*

It lies external to the sheath.

160 *What two sets of branches has it?*

Anterior and posterior.

161 *What are the (2) posterior branches?*

Muscular and articular.

162 *What group of muscles does it supply?*

The extensors.

163 *What nerve supplies the adductors?*

The obturator.

164 *What nerve supplies the flexors?*

The great sciatic.

165 *What are the (3) anterior branches of the anterior crural?*

The internal and middle cutaneous and long saphenous.

166 *What are the branches of the internal cutaneous?*

Anterior and posterior.

167 *What are the branches of the middle cutaneous?*

Internal and external.

168 *What relation do they bear to the sartorius?*

One passes superficial to and the other through the sartorius.

The Long Saphenous Nerve.

169 *Where does the long saphenous pass after leaving Scarpa's triangle?*

Into Hunter's canal.

170 *How does it escape from the canal?*

By piercing the roof.

171 *Between what tendons does it pass?*

The sartorius and gracilis.

172 *What vein does it accompany?*

The long saphenous.

173 *What relation does it bear to the inner malleolus?*

It passes in front of the malleolus?

174 *What does it supply in the foot?*

The inside of the foot as far forward as the ball of the great toe.

The Patellar Plexus.

175 *What (4) nerves form the patellar plexus?*

The internal, middle and external cutaneous, and long saphenous.

The Subsartorial Plexus.

176 *What (3) nerves form the subsartorial plexus?*

The internal cutaneous, long saphenous, and obturator.

The Sacral Plexus.

177 *What nerves form the sacral plexus?*

The lumbo-sacral cord and the four upper sacral nerves.

178 *On what muscle does it lie?*
The pyriformis.
179 *What are its two sets of branches?*
Collateral and terminal.
180 *What are the (5) collateral branches?*
The superior and inferior gluteal, small sciatic, muscular, and visceral.
181 *What are the (2) terminal branches?*
The great sciatic and internal pudic.

The Superior Gluteal Nerve.

182 *How does the superior gluteal nerve escape from the pelvis?*
By the great sacro-sciatic foramen.
183 *In what relation to the pyriformis?*
Above.
184 *What (3) muscles does it supply?*
The gluteus medius and minimus and tensor fasciæ femoris.

The Inferior Gluteal Nerve.

185 *How does the inferior gluteal escape from the pelvis?*
By the great sacro-sciatic foramen.
186 *In what relation to the pyriformis?*
Below.
187 *What muscle does it supply?*
The gluteus maximus.

The Small Sciatic Nerve.

188 *What kind of a nerve is the small sciatic?*
Cutaneous.

189 *How far down the lower extremity does it go?*

To the middle of the leg.

190 *What does it accompany in the upper part of the leg?*

The short saphenous vein.

191 *What are its (2) branches?*

Reflected and pudendal.

192 *Where are the reflected branches given off?*

At the lower margin of the gluteus maximus.

193 *What do they wind around?*

The gluteus maximus.

194 *What muscles does the long pudendal wind around?*

The origin of the hamstring muscles.

195 *What fascia does it pierce?*

Colles'.

196 *What does it supply?*

The scrotum or labium majus.

The Internal Pudic Nerve.

197 *What nerves form the internal pudic nerve?*

The second, third, and fourth sacral.

198 *How does it escape from the pelvis?*

By the great sacro-sciatic foramen.

199 *In what relation to the pyriformis?*

Below.

200 *Around what does it wind?*

The ischial spine.

201 *Through what does it then pass?*
The lesser sacro-sciatic foramen.
202 *What accompanies it?*
The internal pudic artery and vein.
203 *What fossa does it enter?*
The ischio-rectal.
204 *Which wall of the fossa? What fascia?*
The outer wall. The obturator fascia.
205 *What canal in the fascia does it traverse?*
Alcock's.
206 *What branch does it give off while in the canal?*
The inferior hemorrhoidal.
207 *What are its terminal branches?*
The perineal nerve and dorsal nerve of the penis.
208 *Into what does the perineal nerve divide?*
Cutaneous and muscular.
209 *How many cutaneous branches are there?*
Two.
210 *What are they called?*
Anterior and posterior superficial.
211 *What does the muscular branch supply?*
The bulb of the urethra and the perineal muscles.
212 *What relation to the layers of the triangular ligament does the dorsal nerve of the penis bear?*
It lies between them.
213 *Which layer does it pierce?*
The anterior.

The Great Sciatic Nerve.

214 *What nerves form the great sciatic?*

The lumbo-sacral cord and the first, second, and third sacral.

215 *How does it escape from the pelvis?*

By the great sacro-sciatic foramen.

216 *In what relation to the pyriformis?*

Below.

217 *What structures leave the pelvis through the great sacro-sciatic foramen above the pyriformis?*

The superior gluteal nerve and the gluteal artery.

218 *What structures leave below?*

The great and small sciatic, internal pudic, and inferior gluteal nerves, and the sciatic and internal pudic arteries.

219 *What (2) muscles lie posterior to the great sciatic? What nerve?*

The gluteus maximus and biceps. The small sciatic.

220 *What (5) muscles lie anterior?*

The superior gemellus, obturator internus, inferior gemellus, quadratus femoris, and adductor magnus.

221 *What (4) muscles in the thigh does it supply?*

The biceps, semitendinosus, semimembranosus and adductor magnus.

222 *Into what does it divide?*

Internal and external popliteal.

The External Popliteal Nerve.

223 *What tendon does the external popliteal lie close to?*

The biceps.

224 *Between what muscles does it pass?*

The biceps tendon and the outer head of the gastrocnemius.

225 *What are its terminal branches?*

The anterior tibial and musculo-cutaneous.

226 *How many cutaneous branches has it?*

Two.

227 *Which is the more important?*

The nervus communicans fibularis or communicans peronei.

228 *With what does it inosculate? To form what?*

The nervus communicans tibialis or communicans poplitei. The short saphenous.

The Short Saphenous Nerve.

229 *What accompanies the short saphenous nerve?*

The small sciatic and short saphenous veins.

230 *Around which malleolus does it wind?*

The external.

231 *What does it supply?*

The outer side of the foot and little toe.

232 *In what muscle does the recurrent articular end?*

The tibialis anticus.

The Musculo-cutaneous Nerve.

233 *What muscle does the musculo-cutaneous traverse?*

The peroneus longus.

234 *Between what muscles does it then lie?*

The peroneus longus and brevis.

235 *What are its terminal branches?*

Internal and external.

236 *What toes does it supply?*

All except adjacent sides of the great and next toes and the outer side of the little toe.

The Anterior Tibial Nerve.

237 *What muscle does the anterior tibial traverse?*

The peroneus longus.

238 *Between what muscles does it lie in the upper third of the leg? In the middle third? In the lower third?*

Tibialis anticus and extensor longus digitorum. Tibialis anticus and extensor proprius hallucis. Extensor longus digitorum and extensor proprius hallucis.

239 *What relation does it bear to the artery?*

First outside, then in front, then outside or in front.

240 *What are its terminal branches?*

External and internal.

241 *What toes does it supply?*

Adjacent sides of the great and next toes.

The Internal Popliteal Artery.

242 *What (3) relations does the internal popliteal nerve bear to the artery?*

External, posterior, and internal.

243 *What separates it from the artery?*

The popliteal vein.

244 *What is the cutaneous branch of the internal popliteal?*

The nervus communicans tibialis or communicans poplitei.

245 *With what does it inosculate?*

The communicans fibularis to form the short saphenous.

246 *How many articular branches has the internal popliteal? The external popliteal?*

Three. Two.

The Posterior Tibial Artery.

247 *What is the continuation of the internal popliteal?*

The posterior tibial.

248 *What (3) relations does the artery bear to it?*

External, anterior, and internal.

249 *What branch does it give off before it divides?*

The internal calcanean.

250 *Into what does it divide?*

Internal and external plantar.

251 *Which is the larger?*

The internal.

252 *How many toes does it supply?*
Three and a half.
253 *What supplies the other toes?*
The external plantar.
254 *What (7) nerves supply the foot?*
The anterior tibial, musculo-cutaneous, long and short saphenous, internal and external plantar, and internal calcanean.

The Cutaneous Nerve Supply.

255 *What is the cutaneous nerve supply of the front of the thigh?*
The external, middle, and internal cutaneous, ilio-inguinal and genito-crural.
256 *What is the cutaneous nerve supply of the front of the leg?*
The external popliteal, long saphenous, and musculo-cutaneous.
257 *What is the cutaneous nerve supply of the dorsum of the foot?*
The long and short saphenous, musculo-cutaneous, and anterior tibial.
258 *What is the cutaneous nerve supply of the buttock?*
The last thoracic, ilio-hypogastric, posterior branches of the lumbar and sacral nerves, perforating cutaneous branch of the fourth sacral nerve, and small sciatic.
259 *What is the cutaneous nerve supply of the back of the thigh?*
Small sciatic, obturator, and external cutaneous.

260 *What is the cutaneous nerve supply of the back of the leg?*

Small sciatic and long and short saphenous.

261 *What is the cutaneous nerve supply of the sole of the foot?*

Internal calcanean and internal and external plantar.

The Long Saphenous Vein.

262 *How many saphenous veins are there?*

Two.

263 *What are they called?*

Long and short or internal and external.

264 *Where do they begin?*

In an arciform plexus on the dorsum of the foot.

265 *What relation does the long saphenous bear to the inner malleolus?*

It passes in front of the malleolus.

266 *What accompanies it in the leg?*

The long saphenous nerve.

267 *What relation does it bear to the inner femoral condyle?*

It passes behind the condyle.

268 *What opening does it traverse?*

The saphenous opening.

269 *What fascia does it pierce?*

The cribriform fascia.

270 *Where does it empty?*

The femoral vein.

The Short Saphenous Vein.

271 *What relation does the short saphenous bear to the external malleolus?*

It passes behind the malleolus.

272 *What nerve accompanies its lower portion?*

The short saphenous.

273 *What nerve accompanies its upper portion?*

The small sciatic.

274 *What fascia does it pierce?*

The popliteal.

275 *Where does it empty?*

The popliteal vein.

The Muscles.

276 *What are the (4) flexors of the thigh?*

The psoas magnus, iliacus, pectineus, and sartorius.

277 *Which (2) arise in the pelvis?*

The psoas and iliacus.

278 *What (4) muscles arise in the pelvis and pass out?*

Psoas, iliacus, pyriformis and obturator internus.

279 *Where does the psoas magnus arise?*

By five processes from the intervertebral discs between the last thoracic and five lumbar vertebræ, the bodies and transverse processes of the lumbar vertebræ and from tendinous arches.

280 *How does it escape from the pelvis?*
Beneath Poupart's ligament.
281 *Where does it insert? With what?*
The lesser trochanter of the femur. The iliacus.
282 *What plexus arises in its substance?*
The lumbar.
283 *Where does the iliacus arise?*
The ala of the sacrum, the ilio-lumbar, lumbo-sacral and anterior sacro-iliac ligaments, the outer half of the venter of the ilium, the upper tendon of the rectus and the ilio-femoral ligament.
284 *How does it escape from the pelvis?*
Beneath Poupart's ligament.
285 *Where does it insert?*
The lesser trochanter of the femur, and for an inch below it.
286 *Where does the psoas parvus arise?*
From the disc between the last thoracic and first lumbar vertebræ.
287 *Where does it insert?*
The ilio-pectineal line.
288 *Where does the sartorius arise?*
From the anterior superior spine and the notch below it.
289 *Where does it insert?*
The tibia internal to the tubercle, and the deep fascia of the leg.
290 *Where does the pectineus arise?*
The ilio-pectineal line and the pubes and deep fascia in front of the line.

291 *Where does it insert?*

The back of the femur in a two-inch line behind and below the lesser trochanter.

292 *How many layers of gluteal muscles are there?*

Three.

293 *What are the (2) of the first layer? (1) Of the second layer? (1) Of the third layer?*

Gluteus maximus and tensor fasciæ femoris. Gluteus medius. Gluteus minimus.

294 *Where does the gluteus maximus arise?*

The posterior fifth of the outer lip of the crest of the ilium and the ilium between the outer lip and the superior curved line, the lumbar aponeurosis, the last two pieces of the sacrum, the side of the coccyx, the back of the great sacro-sciatic ligament, and the fascia lata over the gluteus medius.

295 *Where does it insert?*

The upper part of the ilio-tibial band, the gluteal ridge, and the adjacent origin of the vastus externus.

296 *Where does the tensor fasciæ femoris arise?*

The front of the outer lip of the iliac crest, the notch below the anterior superior iliac crest, and the inner surface of the fascia lata.

297 *Where does it insert?*

The fascia lata.

298 *Where does the gluteus medius arise?*

The anterior four-fifths of the outer lip

of the iliac crest, the ilium between the crest and superior curved line above and the middle curved line below, and the deep fascia covering both surfaces of the muscle.

299 *Where does it insert?*

The oblique line on the great trochanter.

300 *Where does the gluteus minimus arise?*

The ilium between the inferior and middle curved lines, the deep fascia covering it, and the capsule of the hip joint.

301 *Where does it insert?*

The anterior border of the great trochanter.

302 *What are the (6) external rotators of the thigh?*

The pyriformis, obturator internus, gemellus superior and inferior, quadratus femoris, and obturator externus.

303 *Which (2) arise within the pelvis?*

The pyriformis and obturator internus?

304 *Where does the pyriformis arise?*

The front of the sacrum between the first and fourth foramina, the great sacro-sciatic ligament and the upper margin of the great sacro-sciatic notch.

305 *How does it escape from the pelvis?*

By the great sacro-sciatic foramen?

306 *Where does it insert?*

The anterior part of the upper border of the great trochanter.

307 *What converts the great sacro-sciatic notch into a foramen?*

The small sacro-sciatic ligament.

308 *What converts the small notch into a foramen?*

The great sacro-sciatic ligament.

309 *What separates the two foramina?*

The spine of the ischium.

310 *What passes through both foramina?*

The internal pudic vessels and nerve.

311 *Where does the obturator internus arise?*

The body and descending ramus of the pubes, the ascending ramus of the ischium, the inner surface of the obturator membrane, the bone behind the obturator foramen and the pelvic and obturator fascias.

312 *Where does it insert?*

The inner surface of the upper border of the great trochanter.

313 *How does it escape from the pelvis?*

By the lesser sacro-sciatic foramen.

314 *What (2) muscles insert with it?*

The gemelli.

315 *What (4) structures pass through this foramen?*

The obturator internus, internal pudic vessels and nerve, and muscular branches of the sacral plexus.

316 *Where does the gemellus superior arise?*

The spine of the ischium and the upper margin of the lesser sacro-sciatic notch.

317 *Where does it insert?*

The upper and anterior surfaces of the obturator internus tendon.

318 *Where does the gemellus inferior arise?*

The tuber ischii and the lower margin of the lesser sacro-sciatic foramen.

319 *Where does it insert?*

The lower and anterior surfaces of the obturator internus tendon.

320 *Where does the quadratus femoris arise?*

The tuber ischii.

321 *Where does it insert?*

The linea quadrati.

322 *Where does the obturator externus arise?*

The inner half of the outer surface of the obturator membrane, the descending ramus of the pubes, and the ascending ramus of the ischium.

323 *Where does it insert?*

The digital fossa.

324 *What are the (3) hamstring muscles?*

The biceps femoris, semitendinosus, and semimembranosus.

325 *Where does the biceps femoris arise?*

The long head from the tuber ischii in common with the semitendinosus and from the great sacro-sciatic ligament; the short head from the lower part of the linea aspera and its outer division, and the external intermuscular septum.

326 *Where does it insert?*

The head of the fibula, the outer tuberosity of the tibia and the deep fascia.

327 *Where does the semitendinosus arise?*

With the biceps from the tuber ischii.

328 *Where does it insert?*

The upper part of the tibia and the deep fascia.

329 *Where does the semimembranosus arise?*

The tuber ischii.

330 *Where does it insert?*

The inner tuberosity of the tibia, the posterior ligament of the knee-joint, the popliteus fascia, and the internal lateral ligament.

331 *What muscles form the quadriceps extensor femoris?*

The rectus, vastus internus, vastus externus, and crureus.

332 *Which arises from the innominate bone?*

The rectus.

333 *Where do the others arise?*

From the femur.

334 *Where do they all insert?*

Into the patella.

335 *Where does the rectus femoris arise?*

The anterior head from the anterior inferior iliac spine; the posterior head from the upper margin of the acetabulum.

336 *Where does it insert?*

The patella.

337 *Where does the vastus externus arise?*

The upper half of the anterior intertrochanteric line, the femur along the anterior border of the great trochanter, the lower border of the great trochanter, the outer lip of the gluteal ridge, the upper half of the outer lip of the linea aspera, and adjacent

portion of the femur and the external intermuscular septem.

338 *Where does it insert?*

The patella, the outer tuberosity of the tibia, and the deep fascia.

339 *Where do the vastus internus and crureus arise?*

The external intermuscular septum, the outer lip of the lower half of the linea aspera and its outer limb, the lower part of the anterior intertrochanteric line, the spiral line, the inner lip of the linea aspera and its inner limb with the adjacent internal intermuscular septum, the tendon of the adductor magnus, and the front and sides of the femur.

340 *Where does it insert?*

The patella, the outer tuberosity of the tibia, and the deep fascia.

341 *What is the common tendon of the quadriceps called?*

The ligamentum patellæ.

342 *How many layers of muscles are there on the back of the leg?*

Two above and four below.

343 *What (2) muscles form the first layer?*

The gastrocnemius and plantaris.

344 *What is the origin of the gastrocnemius?*

The outer head from the external condyle and femur above it; the inner head from the femur above the internal condyle.

345 *Where does it insert?*

By the tendo Achillis into the posterior surface of the os calcis.

346 *Where does the plantaris arise?*

The lower part of the outer limb of the linea aspera and the posterior ligament of the knee.

347 *Where does it insert?*

By the longest tendon in the body, into the inner side of the posterior surface of the os calcis.

348 *What (2) muscles form the second layer?*

The popliteus and soleus.

349 *What is the origin of the popliteus?*

The external condyle and posterior ligament.

350 *Where does it insert?*

The back of the tibia above the oblique line and the fascia from the semimembranosus tendon.

351 *Where does the soleus arise?*

The oblique line and inner border of the posterior surface down to the middle of the tibia, the head and upper third of the fibula, intermuscular septa and a tendinous arch between the upper portions of the tibia and fibula.

352 *Where does it insert?*

Through the tendo Achillis.

353 *What separates the second and third layers?*

The deep tibial or transverse fascia.

354 *What (2) muscles comprise the third layer?*

The flexor longus digitorum and flexor longus hallucis.

355 *Where does the flexor longus digitorum arise?*

The inner part of the posterior surface of the tibia from the oblique line to three inches above the inner ankle, the deep fascia and the intermuscular septum.

356 *Which malleolus does it pass around?*

The inner.

357 *Where does it insert?*

The base of the last phalanx of the four outer toes.

358 *What muscle inserts into it?*

The flexor accessorius.

359 *Where does the flexor longus hallucis arise?*

The lower two-thirds of the fibula, intermuscular septa, the deep fascia over the muscle, and the lower part of the interosseous membrane.

360 *What malleolus does it pass around?*

The inner.

361 *Where does it insert?*

The base of the last phalanx of the great toe and the tendon of the flexor longus digitorum passing to the second and third toes.

362 *What muscle comprises the fourth layer?*

The tibialis posticus.

363 *Where does the tibialis posticus arise?*

The interosseous membrane, except the lower portion; the tibia from the oblique line

to the junction of the middle and lower thirds; the fibula, except its lower inch or two; intermuscular septa and fascia.

364 *What malleolus does it wind around?*

The inner.

365 *Where does it insert?*

Mainly the tuberosity of the scaphoid bone; also the tarsal bones, except the astragalus; and the bases of the second, third and fourth metatarsal bones.

366 *What are the (4) muscles on the front of the leg?*

The tibialis anticus, extensor proprius hallucis, extensor longus digitorum, and peroneus tertius.

367 *Where does the tibialis anticus arise?*

The outer tuberosity and upper two-thirds of the tibia, the interosseous membrane, deep fascia, and intermuscular septum.

368 *Where does it insert?*

The internal cuneiform and base of the first metatarsal bone.

369 *Where does the extensor proprius hallucis arise?*

The middle two-fourths of the fibula and the adjacent interosseous membrane.

370 *Where does it insert?*

The base of the second phalanx and the back and sides of the metatarso-phalangeal articulation of the great toe.

371 *Where does the extensor longus digitorum arise?*

The outer tuberosity of the tibia, the upper three-fourths of the fibula, the upper third of the interosseous membrane, the deep fascia, and intermuscular septa.

372 *Where does it insert?*

The metatarso-phalangeal joints and all three phalanges of the outer four toes.

373 *Where does the peroneus tertius arise?*

The lower fourth of the fibula, the lower inch or two of the interosseous membrane, the external intermuscular septum, and deep fascia.

374 *Where does it insert?*

The base of the fifth metatarsal bone.

375 *What muscle is there on the dorsum of the foot?*

The extensor brevis digitorum.

376 *Where does it arise?*

The great process of the calcaneum and the anterior annular ligament.

377 *Where does it insert?*

By four tendons, the inner at the base of the first phalanx of the great toe and the other three in the tendons of the extensor longus digitorum.

378 *What (2) muscles form the peroneal group or muscles on the outer side of the leg?*

The peroneus longus and brevis.

379 *Where does the peroneus longus arise?*

The outer tuberosity of the tibia, the head and upper two-thirds of the fibula, the deep fascia, and intermuscular septa.

380 *Where does it insert?*

The base of the first metatarsal bone and the internal cuneiform.

381 *Where does the peroneus brevis arise?*

The lower two-thirds of the fibula, the deep fascia, and intermuscular septa.

382 *Where does it insert?*

The base of the fifth metatarsal bone and the tendon of the extensor longus digitorum.

The Plantar Facia.

383 *How many portions has the plantar fascia?*

Three.

384 *What are they?*

A central and two lateral.

385 *Where is the central portion attached posteriorly?*

To the calcaneum.

386 *Into how many processes does it break up?*

Five, one for each toe.

387 *What do they bind down?*

The flexor tendons.

388 *What structures pass between them?*

Digital vessels and nerves.

389 *What are the margins of the central portion prolonged to form?*

The external and internal intermuscular septa.

390 *Where is the inner portion attached?*

Behind to the great tubercle of the os calcis and the internal annular ligament and

in front to the base of the first phalanx of the great toe.

391 *Where is the outer portion attached?*

Behind to the lesser tubercle of the os calcis and the external annular ligament, and in front to the base of the first phalanx of the little toe.

The Muscles.

392 *How many layers of muscles are there in the sole of the foot?*

Four.

393 *What are the (3) muscles of the first layer?*

The abductor hallucis, flexor brevis digitorum, and abductor minimi digiti.

394 *Where does the abductor hallucis arise?*

The outer head from the great tubercle of the calcaneum, the plantar fascia and internal intermuscular septum; the inner head from the inner annular ligament and the attachment of the tendon of the tibialis posticus to the scaphoid bone.

395 *Where does it insert?*

The base of the first phalanx of the great toe.

396 *Where does the flexor brevis digitorum arise?*

The great tubercle of the calcaneum, the plantar fascia, and the two intermuscular septa.

397 *Where does it insert?*

By four tendons, which split to transmit the tendons of the flexor longus digitorum and then insert into the middle phalanx of the four outer toes.

398 *Where does the abductor minimi digiti arise?*

The lesser tubercle and adjacent surface of the calcaneum, the plantar fascia, the external intermuscular septum, and ligaments of the sole of the foot.

399 *Where does it insert?*

The base of the first phalanx and of the metatarsal bone of the little toe and the fourth tendon of the extensor longus digitorum.

400 *What (4) muscles form the second layer?*

The flexor accessorius, the four lumbricales, and the tendons of the flexor longus hallucis and flexor longus digitorum muscles.

401 *Where does the flexor accessorius digitorum arise?*

The inner head from the calcaneum below the groove for the flexor longus hallucis, and the outer head from the calcaneum in front of the lesser tubercle and the long plantar ligament.

402 *Where does it insert?*

The tendon of the flexor longus digitorum.

403 *Where do the lumbricales arise?*

The first from the inner side of the first tendon, and the other three from adjacent sides of the second, third and fourth tendons of the flexor longus digitorum.

404 *Where do they insert?*

The expansion of the tendon of the extensor longus digitorum on the back of the first phalanx of the four outer toes.

405 *What* (4) *muscles form the third layer?*

The flexor brevis hallucis, the adductor hallucis, the transversus pedis, and the flexor brevis minimi digiti.

406 *Where does the flexor brevis hallucis arise?*

The plantar ligaments, the tibialis posticus tendon, and the cuboid bone.

407 *Where does it insert?*

The base of the first phalanx of the great toe.

408 *Where does the adductor hallucis arise?*

The sheath of the peroneus longus tendon and the base of the second, third, and fourth metatarsal bones.

409 *Where does it insert?*

Base of the first phalanx of the great toe.

410 *Where does the transversus pedis arise?*

The plantar ligaments of the three outer metatarso-phalangeal joints and the deep transverse metatarsal ligament.

411 *Where does it insert?*

Base of the first phalanx of the great toe.

412 *Where does the flexor brevis minimi digiti arise?*

The base of the fifth metatarsal bone and the sheath of the peroneus longus tendon.

413 *Where does it insert?*

The base of the first phalanx of the little toe and the front of the fifth metatarsal bone.

414 *What muscles form the fourth layer?*

The interossei.

415 *How many plantar interossei are there?*

Three.

416 *How many dorsal?*

Four.

417 *Where do the plantar interossei arise?*

The lower inner surface of the three outer metatarsal bones and the sheath of the peroneus longus.

418 *Where do they insert?*

The base of the first phalanx of the three outer toes and the extensor tendons on the back of the first phalanx of these toes.

419 *Where do the dorsal interossei arise?*

By two heads from the adjacent surface of the five metatarsal bones.

420 *Where do they insert?*

The base of the first phalanx of the second, third, and fourth toes, the second toe receiving the insertion of two.

421 *What passes between the heads of the first dorsal interosseous?*

The communicating branch of the dorsalis pedis artery.

422 *What passes between the heads of the outer three?*

posterior perforating arteries.

The base of the first phalanx of the little toe and the front of the fifth metatarsal bone.

414 *What muscles form the fourth layer?*

The interossei.

415 *How many plantar interossei are there?*

Three.

416 *How many dorsal?*

Four.

417 *Where do the plantar interossei arise?*

The lower inner surface of the three outer metatarsal bones and the sheath of the peroneus longus.

418 *Where do they insert?*

The base of the first phalanx of the three outer toes and the extensor tendons on the back of the first phalanx of these toes.

419 *Where do the dorsal interossei arise?*

By two heads from the adjacent surface of the five metatarsal bones.

420 *Where do they insert?*

The base of the first phalanx of the second, third, and fourth toes, the second toe receiving the insertion of two.

421 *What passes between the heads of the first dorsal interosseous?*

The communicating branch of the dorsalis pedis artery.

422 *What passes between the heads of the outer three?*

The posterior perforating arteries.

LANE MEDICAL LIBRARY

To avoid fine, this book should be returned on
or before the date last stamped below.

MAR 21 1932
NOV 28 1964
MAR 13 1972
AUG 25 1973

LANE MEDICAL LIBRARY OF
STANFORD UNIVERSITY
300 PASTEUR ROAD
PALO ALTO, CALIFORNIA

E32 Fetterolf, G.
F42 Questions on practical
1899 anatomy. 72783

NAME	DATE DUE
Edgar J. Poth	MAR 21 1932
Fred Fellows	JUL 19 1932
E. J. Poth	AUG 15 1935
Mary Helen Brown Spt	NOV 28 1964
315-3 Stanford Village	MAR 13 1972
N. Ebbert I	AUG 25
R. Felder III	
SEP 12 1973 PC	